

Current Methods for the Diagnosis and Treatment of Choroidal Melanoma

Vasileios Petousis, MD¹ and Paul T Finger, MD²

1. Fellow; 2. Director, The New York Eye Cancer Center

Abstract

Choroidal melanoma is the most common primary intraocular malignancy. Diagnosis is performed by clinical evaluation: eye cancer specialists currently use multiple diagnostic techniques, including ophthalmoscopy, fundus autofluorescence imaging (FAF), fluorescein angiography (FA), and indocyanine green angiography (ICG), as well as optical coherence tomography (OCT). Tumor biopsy has recently become popular due to the availability of diagnostic cytogenetic features, touted as biomarkers for metastasis. Standard treatments include observation (select small melanomas and indeterminate tumors), radiation therapy (plaque, proton beam), eye wall resection, and removal of the eye. Of these, ophthalmic plaque radiation therapy has become the most common and widely available conservative treatment. Successful initial treatment offers the best chance to prevent subsequent metastasis. Metastatic choroidal melanoma is typically diagnosed by combinations of physical examination, hematologic surveys, abdominal radiographic imaging (ultrasound, magnetic resonance imaging, computed tomography), and positron emission tomography–computed tomography (PET/CT). Most often initially found in the liver, metastatic choroidal melanoma carries an unfavorable prognosis for life. Herein, we report on currently available methods of diagnosis and treatment for choroidal melanoma.

Keywords

Choroid, melanoma, diagnosis, treatment, staging

Disclosure: Vasileios Petousis, MD, has received a fellowship grant from The Eye Cancer Foundation, Inc. Paul T Finger, MD, has no conflicts of interest to declare.

Received: September 1, 2010 **Accepted:** September 1, 2011 **Citation:** *US Ophthalmic Review*, 2012;5(1):62–9 DOI: 10.17925/USOR.2012.05.01.62

Correspondence: Paul T Finger, MD, The New York Eye Cancer Center, 115 East 61st Street, New York City, NY 10065. E: pfinger@eyecancer.com

Choroidal melanoma (CM) is both the most common form of uveal melanoma and the most frequent primary intraocular malignancy. There is a reported yearly incidence of 4–6 per million per year in the US and Europe. Of interest, Queensland, Australia (beneath the ozone hole) has the highest reported incidence (10 per million per year) worldwide.¹ While ultraviolet (UV) radiation has been proved to play a role in the pathogenesis of cutaneous melanoma, the statistical link for CM has been less clear. Factors implicating UV radiation in the incidence of CM include an increased incidence in patients with blue irises, outdoor occupations, and that these tumors are most commonly found in the posterior uvea, the choroid.¹

CMs can present with or without symptoms.² Size, location, and tumor-related secondary complications (e.g. detachment, hemorrhage, cataract, and glaucoma) are associated with a variety of clinical symptoms. Symptomless patients are typically discovered during the course of periodic ophthalmic examinations or incidentally when patients seek refraction. Once found, CMs are typically sent to regional referral centers where further evaluations include extended ophthalmoscopy and specialized photography (e.g. color imaging, fundus autofluorescent imaging [FAF], fluorescein angiography [FA], and indocyanine green angiography [ICG]), as well as optical coherence tomography (OCT).^{3–6} Each diagnostic method has been shown to offer unique capabilities to reveal the diagnostic characteristics of CM.

Radiographic studies, such as magnetic resonance imaging (MRI), computed tomography (CT), and positron emission tomography–computed tomography (PET/CT) are also selectively employed to evaluate CM.^{7–11} However, these techniques are more commonly used for systemic screening for metastatic disease.^{12,13}

CM treatment has evolved from primary enucleation and local resection to eye-, sight-, and vision-sparing radiotherapy techniques. Stallard introduced the first eye plaques.¹⁴ These first disk-shaped radiation therapy devices contained cobalt-60 and were later replaced by ruthenium-106, iodine-125, and palladium-103 sources.^{15–17} Each radionuclide offers a unique and different intraocular dose distribution. Select centers have also used external beam radiation therapy (EBRT). The most common eye- and vision-sparing EBRT is proton beam.¹⁸ More exotic forms of EBRT include the gamma-knife and stereotactic radiosurgery.¹⁹

The Collaborative ocular melanoma study (COMS) was a three-arm trial that included two multicenter prospective randomized clinical studies. A 16-year effort, the COMS stands as the largest evidence-based study of CM. Of the three clinical arms, the small tumor study found that 31 % of small CMs were documented to grow over five years.²⁰ The medium-sized tumor trial found no survival benefit from enucleation (removal of the eye) versus episcleral iodine-125 plaque irradiation.¹⁶ The large CM study (an indirect test of the Zimmerman Hypothesis: that enucleation surgery

disseminated metastases) found that pre-enucleation EBRT (2 Gy x five daily fractions) did not improve post-enucleation survival.²¹ Though the COMS had a significant impact on practice patterns, much has changed over subsequent years. Current practice patterns are based on the characteristics of the CM, visual acuity, treatment modalities available and the patients' motivation to keep their eye, as well as regional, political, and socioeconomic factors.

The Diagnosis of Choroidal Melanoma

Detection

In the UK, 45 % of CM patients were reported to be asymptomatic at diagnosis.²² In these cases, CM is an accidental finding during a routine periodic ophthalmic examination. In all other cases, patients present with symptoms of visual loss, metamorphopsia, flashing lights, or floaters. Less common findings have been related to secondary effects, such as cataract, narrow-angle glaucoma, or vitreous hemorrhage. It is not uncommon for a CM to be missed at initial examination, particularly with small ciliary body tumors. The rates of failure to diagnose have been reported within a range of 25–37 %.²² Eye cancer specialists should inquire about a past medical history of primary lung, breast, or other cancers, systemic diseases, or anticoagulant therapy. These answers may help differentiate CM from simulating lesions.

Anterior Segment Examination

CMs can affect the anterior segment. Common findings include 'sentinel' episcleral blood vessels. Less commonly, the tumor can push on the natural lens, inducing a sector cataract (with irregular astigmatism) or angle narrowing. Secondary glaucoma can be seen as irisneovascularization, outflow invasion, or angle closure.²³ CMs with massive orbital extension can be associated with proptosis, papilledema, and exposure keratopathy. These cases may also exhibit an afferent pupillary and/or color vision deficit, as well as ocular motor disturbances.

Ophthalmoscopy

Most CMs can be diagnosed by ophthalmoscopy (see *Figure 1*). Direct, indirect, and contact lens techniques are employed. Visualization of a pigmented choroidal tumor with the orange pigment lipofuscin (OPL) on the tumor's surface, significant thickness, and exudative retinal detachment are diagnostic of CM.²⁴ For smaller tumors, photography and ultrasound-assisted documentation of growth may be required.

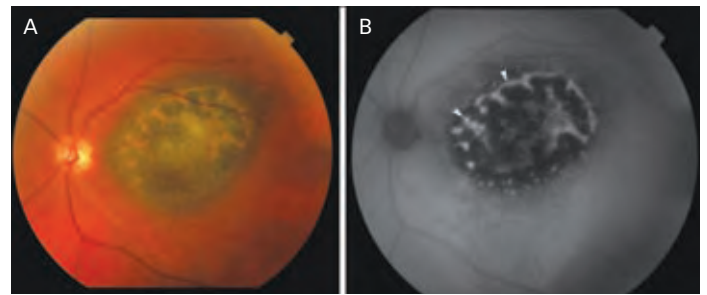
Over the last 30 years, the misdiagnosis rate for CM has been greatly reduced. For example, the use of experienced examiners, indirect ophthalmoscopy, FA, and ultrasound imaging reduced the COMS misdiagnosis rate to less than 1 %.^{25,26}

Ophthalmic Imaging Techniques

Fundus photography, FAF, and OCT have significantly contributed to the diagnosis and understanding of CM and its associated comorbidities.

Fundus photography plays a unique, central, and indispensable role in the diagnosis and follow-up of CM. Photography should be used to document the initial tumor size, to measure its basal dimensions, and to document its surface characteristics. Furthermore, the distances from the posterior tumor edge to the fovea and optic disk should be recorded. These measurements can be used to help the clinician determine radiation dose

Figure 1: Subfoveal Choroidal Melanoma



A: Note the pigmented, subfoveal, and juxtapapillary choroidal melanoma with overlying orange pigment lipofuscin (OPL); B: Fundus autofluorescent imaging (FAF) picture of the same tumor demonstrates hyperautofluorescence of the OPL (arrow heads) and dependent alterations of the retinal pigment epithelium due to a serous retinal detachment.

to critical structures and risks for vision loss. Photographic evidence of tumor-associated exudative subretinal fluid, choroidal neovascularization, OPL deposition, and retinal pigment epithelial metaplasia at first offers diagnostic significance and post-treatment measures of tumor response. For example, after treatment exudative fluid and OPL typically regress and the tumor darkens. Photographic documentation of these changes allows the eye cancer specialists to establish the pattern of CM regression. Late radiation changes (including radiation retinopathy and optic neuropathy) can be initially documented and comparatively evaluated for progression or regression by fundus photography.²⁷

FAF has emerged as a powerful tool to document and discover occult OPL. Exudative retinal detachments can also be seen with FAF, particularly when there is an associated acute or chronic retinal pigment epithelial degeneration.^{3,28}

OCT is the most sensitive method of detecting subretinal fluid and intraretinal edema.²⁹ OPL can also be seen as deposits on the retinal pigment epithelium. Some studies suggest that choroidal nevi and their overlying intact retinal pigment epithelium are less likely to allow transmission of light into the tumor's stroma and subjacent choroid.

Intraocular Angiography

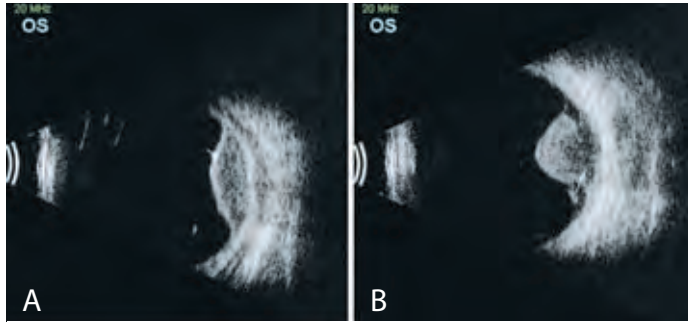
FA and ICG are used to evaluate CM. Angiographic imaging can reveal unique patterns of tumor circulation. For example, a 'double circulation' with well-defined blood vessels is rarely seen in metastatic tumors and a 'coarse vascular pattern' is characteristic of choroidal hemangioma. Metastatic choroidal tumors typically have poor circulation, characterized by slow uptake, leakage, and stromal dot-like microaneurysms. In select cases, FA or ICG may be the best methods to determine largest basal tumor dimensions prior to the choice of plaque size.

Beyond diagnosis, post-treatment surveillance of tumor circulation can help determine response to radiation, adjuvant laser therapies, and the onset of secondary vasculopathy (e.g. radiation maculopathy and optic neuropathy).

Ultrasound Imaging

Ultrasound imaging has come to play an essential role in the diagnosis, treatment, and follow-up of patients with CM. Pioneered by Karl Ossoinig and Sandra Frazier Byrne, standardized ophthalmic ultrasound techniques

Figure 2: B-scan Ultrasound Image of a Dome-shaped and Mushroom-shaped Choroidal Melanoma



B-scan ultrasound image of a dome-shaped choroidal melanoma (a) and a mushroom-shaped choroidal melanoma (b). Note that the internal reflectivity of both tumors is moderately low (arrows), though the head of the mushroom is relatively hyperechoic.

were employed by the COMS and thus established low internal reflectivity and dome shape as the most common presenting characteristics of CM (see Figure 2a).³⁰ Mushroom-shaped CM were noted in only 25 % of cases and found to be more common among larger tumors (see Figure 2b). The COMS report number 29, describing baseline echographic characteristics of 2,320 patients with medium and large tumors, found that 1,268 patients (54 %) had a tumor apex located posterior to the equator (27 % equator-posterior, 22 % posterior-equator, and only 5 % posterior).³⁰

A-scan imaging is the most sensitive method to assess a tumor's internal acoustic reflectivity. This characteristic has been exploited to differentiate between types of tumors and to monitor response to therapy. For example, internal reflectivity is typically high with choroidal hemangioma, moderate with metastases, and low with CM.³¹ Non-hemorrhagic retinal pigment epithelial detachments and choroidal effusions are typically echolucent. During the years after radiation therapy for choroidal melanoma, A-scan typically reveals increasing internal reflectivity.

B-scan imaging has become an essential tool for measuring tumor dimensions. Commonly, CMs are measured to be larger by ultrasound compared with fundus photography. This information is vital for treatment planning (accurate plaque size selection) and for assessing response to radiotherapy. Furthermore, both dynamic A- and B-scan imaging can be used to assess a tumor's intrinsic vascularity at diagnosis and document post-treatment reductions over time.

Use of 3D B-scan ultrasound imaging has proved invaluable for evaluating disorganized eyes (e.g. those containing occult CM). Interactive sectioning of the 3D block has allowed for post-enucleation ultrasonographic-histopathologic reconstruction. Lastly, such sectioning also allows for simultaneous longitudinal and transverse views of ophthalmic plaques *in vivo*, aiding intra-operative evaluations of plaque placement.²⁵ Ophthalmic ultrasound imaging has been recognized as an integral method for evaluating and T-staging uveal melanomas by both the American Joint Committee on Cancer and the International Union Against Cancer.^{20,32-34}

Intraocular Radiographic Imaging

MRI and radiographic CT have limited diagnostic value for the diagnosis of CM. In special circumstances, MRI can be used to help differentiate

between choroidal hemorrhage and CM. It is also used to localize CM prior to endoresection when there are opaque media. Both MRI and CT are essential in evaluating extrascleral, intraneural, or intracranial CM extension.

PET/CT has recently been used to characterize CM. Using 18-fluorodeoxyglucose uptake, PET/CT allows *in vivo* measurements of metabolic activity within CM, though only relatively large CMs were found to be specific uptake value (SUV)-positive. However, this characteristic may be a biomarker for metastasis. In one study, an SUV greater than 4.0 was correlated to such currently accepted tumor high-risk factors as epithelioid cell type, high-risk vascular loops, extrascleral tumor extension and metastases.¹⁰ A recent report found that plaque irradiation extinguished SUV positivity and therefore metabolic activity of CM.³⁵

Intraocular Tumor Biopsy

Since CM can be diagnosed by clinical evaluation and testing in over 99 % of cases, one must question the need for biopsy. On the other hand, if there existed a risk-free method to retrieve a piece of tumor, such tissue would serve to confirm the clinical diagnosis as well as offering helpful histopathologic, genetic, and molecular information. Unfortunately, choroidal biopsy carries the risks (albeit small) of endophthalmitis, vitreous hemorrhage, retinal detachment, and CM dissemination. Therefore, we must weigh the risks versus such potential benefits. Most ophthalmic oncologists agree that biopsy is indicated for atypical tumors where the diagnosis is unclear, when the tumor is probably metastatic with no known primary, and when the patient requires a biopsy to proceed with treatment.³⁶

With advances in cytogenetics, in recent years it appeared likely that biopsy would also be used to grade uveal melanomas. In the 1990s, it was discovered that uveal melanomas tend to develop several chromosomal abnormalities, the most important of which are monosomy 3, isochromosome 6p, trisomy 8, and isochromosome 8q.³⁷ A landmark article by Prescher et al. showed monosomy 3 to correlate strongly with metastatic death, data indicating a reduction in the five-year survival from 100 to less than 50 %.³⁸ However, these initial expectations regarding the sensitivity and specificity of monosomy 3 tests in predicting metastatic death were found to be overly optimistic. Perhaps cytogenetic prognostication may require taking into account the complex pathway we call metastasis and that immune status, tumor size, and access to routes of egress may also play a role.

More recently, Harbour and Onken have introduced the concept of RNA-based analysis, dividing CM into 'type 1' and 'type 2' tumors. According to their study, type 1 tumors carry a low risk of metastasis, while type 2 are mostly lethal.³⁹ These data are admittedly preliminary and require validation by a large clinical study. In the interim, we know of no ophthalmic oncologist who would deny treatment to a type 1 CM based on genetic testing. In summary, cytogenetic classification (both monosomy 3 and RNA analysis) should be considered investigational.

Biopsy methods have been reported to employ a fine needle or vitreous cutter. Approaches include the pars plana, cornea (for anterior segment

tumors), and trans-scleral aspiration into the tumor's base. Ocular oncologists are not unanimous about which option is better, or whether a stepwise approach starting with a fine-needle aspiration biopsy (FNAB) is possible. No matter which approach is taken, potential dissemination of tumor cells remains a concern.⁴⁰

Biomarkers for Metastases

The first biomarkers for CM were histopathologic as offered by Callender's classification, in which predominantly spindle cell melanomas carried the best prognosis, mixed-cell tumors were worse, and epithelioid cell tumors the most likely to metastasize.⁴¹ Other features associated with systemic prognosis include intrinsic tumor vascular patterns, tumor vascular density, tumor size, location of the anterior margin of the tumor, and degree of ciliary body involvement.^{42,43} It is important to note that in consideration of most of the above, as well as epidemiologic and other clinical factors, the COMS offered the first evidence-based results that patient age and largest tumor dimension were the most significant biomarkers for metastasis by multivariate analysis.¹⁶ In 2006, Finger and colleagues suggested that PET/CT imaging specific uptake value (SUV) could be used as a biomarker for metastatic risk.¹⁰ This observation was recently confirmed by Lee et al., 2011.⁴⁴

Metastatic Disease Detection

Although CM is not as aggressive as skin melanoma, Kujala et al. reported mortality rates of 31 % by five years, 45 % by 10 years, 49 % by 25 years, and 52 % by 35 years.⁴⁵ In this article, we found that the diagnosis and treatment of metastatic CM varies by country, region, and clinical centers. It is also driven by patient and social and economic factors.

In general, pre-operative metastatic surveys should include a physical examination looking for cutaneous and subcutaneous nodularity as well as hepatomegaly. Radiographic imaging can range from contrast-enhanced abdominal MRI, CT or ultrasound imaging to total body PET/CT.

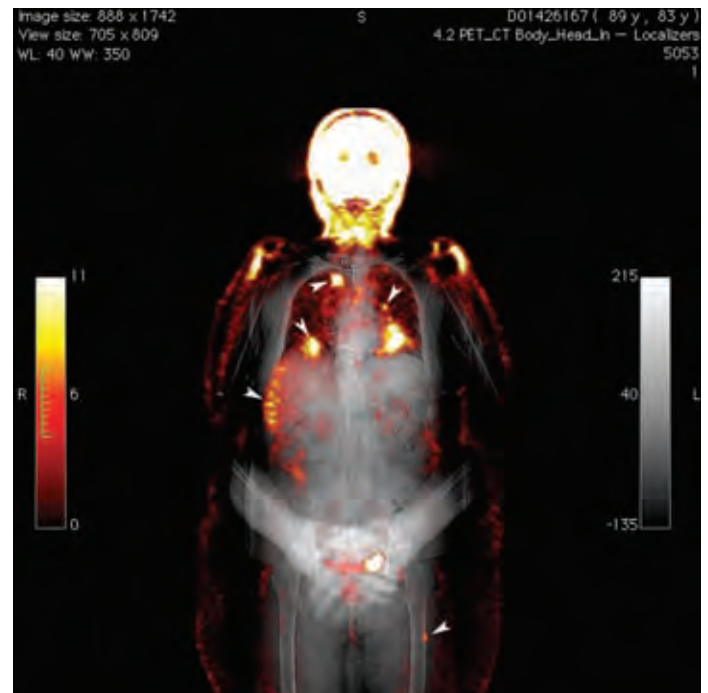
In that over 90 % of patients present with hepatic involvement, abdominal imaging should be integral to pre-operative staging and subsequent surveillance. However, in a recent study using whole-body PET/CT, 75 % of patients with metastatic CM were noted to have extrahepatic – primarily bone (50 %), lung (25 %), lymph node (25 %), and skin (25 %) – metastases (see *Figure 3*). This distribution suggests that liver function tests alone are inadequate.^{24,46,47}

There are centers that do not perform metastatic surveys due to a lack of definitive treatment for metastatic CM. At The New York Eye Cancer Center, we currently perform pre-operative surveys to find the <4 % that have detectable disease at presentation.¹² Such discovery can eliminate the need for surgery for the primary CM, reveals synchronous non-ocular tumors, and allows for both systemic staging and early intervention. Follow-up metastatic surveys allow for both early intervention and end-of-life planning.

Tumor Staging

Clinical practice varies greatly from one center to another. Though the COMS defined CMs as small, medium, and large, the Ophthalmic

Figure 3: Metastatic Choroidal Melanoma (Arrows) as Seen on Positron Emission Tomography/Computed Tomography



Positron emission tomography (PET) reveals a radioactive glucose (18-FDG) uptake measure of physiologic activity, while computed tomography (CT) reveals its anatomic shape and location. This combined PET/CT image puts form and function on the same diagnostic page.

Oncology Task Force of the AJCC, together with the UICC, has recently produced a universally accepted seventh edition AJCC staging system. This five-year effort involved 45 eye cancer specialists from 11 countries.⁴⁸

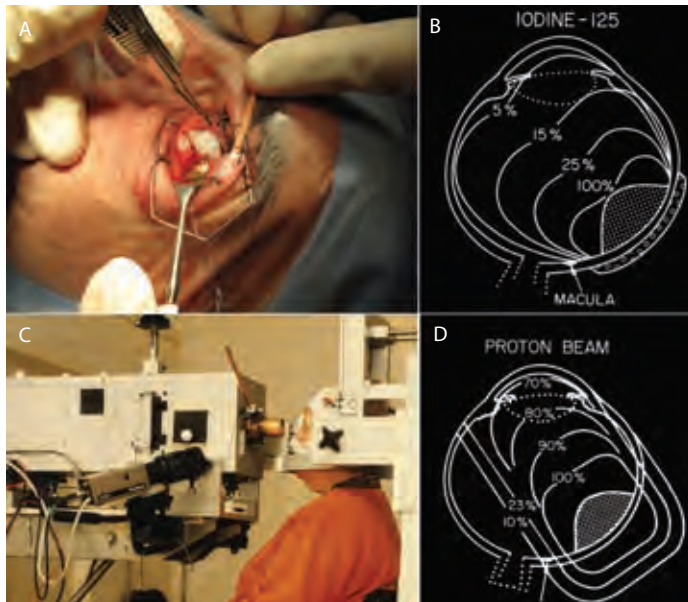
Specifically, Chapter 51, Malignant Melanoma of the Uvea, was the result of a retrospective multinational evaluation of over 8,000 patients. This system is now considered 'universal' after being widely accepted as a requirement for publication by over 10 major ophthalmic journals and their associated societies. They recognized that standardized reporting would allow for more accurate comparison of diagnostic and therapeutic techniques, as well as the development of biomarkers for CM.

Diagnosis of Choroidal Melanoma—Summary

Findings of OPL, thickness greater than 2 mm and subretinal fluid remain the most important diagnostic characteristics of CM. These characteristics are evaluated by ophthalmoscopy, photography with and without angiography, and ophthalmic ultrasound imaging.

Specialized FAF and OCT imaging offer unique and often helpful information about the presence of OPL and subretinal fluid. Ultrasound is best at uncovering obscure basal extensions, vascularity, shifting exudative fluid, scleral extension, and tumor height. Despite all this technology, small CM and indeterminate lesions are typically considered too small for biopsy and are followed for evidence of growth prior to intervention. In summary, clinical, photographic, and ultrasound imaging techniques are currently employed for initial assessment, evaluation of post-treatment regression, and side effects.

Figure 4: Radioactive Plaque Brachytherapy (Top) Versus Proton Beam Teletherapy (Bottom)



A: An intra-operative photograph shows surgical placement of an ophthalmic plaque; B: A graphic demonstration of the relative dose distribution of an I-125 plaque; C: A photograph of a patient receiving proton beam radiation; D: A graphic demonstration of the relative dose distribution of transocular proton beam radiation. Note that the tantalum clips have been surgically placed, now the patient requires head immobilization, and a video camera is used to monitor eye movements.

The Treatment of Choroidal Melanoma Treatment

CM treatment is performed to prevent metastatic disease, to maximize visual acuity, and to preserve the eye. With these goals in mind, there has been an evolution of treatment from primary enucleation and local resection to laser photocoagulation and radiation therapy. At this time, radiation therapy is the most widely accepted alternative to enucleation.⁴⁹

Enucleation

In most developed countries, enucleation surgery is performed when the CM is considered to be too large for vision-sparing techniques, for extensive extrascleral tumor extension, and for neovascular glaucoma.⁵⁰ Alternatively, in undeveloped countries eye- and vision-sparing radiation techniques may not be available. The COMS large tumor trial found that 20 Gy (4 Gy per day x five 5 days) did not improve survival after enucleation surgery.⁵¹ This finding suggests that the Zimmerman Hypothesis (that we disseminated metastasis by manipulation during enucleation surgery) was incorrect.⁵² It is important to note that orbital tumor recurrence was reported in less than 1 % of cases. If this occurs, it can be treated by local resection of all visible tumor, followed by 50 Gy external beam radiotherapy.⁵³

At The New York Eye Cancer Center, most patients can be fitted with an ocular prosthesis that requires minimal maintenance and has excellent cosmesis.⁵⁴ Prosthetic ocular motility is typically less than the natural eye and mucus discharge is common. Patients should be counseled to wear unbreakable polycarbonate glasses to protect the remaining eye.

Local Resection Techniques

Endoresection

Endoresection comprises the removal of a posteriorly located uveal melanoma through a pars plana vitrectomy, typically after radiation therapy.⁵⁵ Surgery is performed with a vitrector through a retinotomy or beneath a retinal flap. An air-fluid exchange drains residual subretinal fluid; endolaser photocoagulation is used to destroy any residual intrascleral tumor and to achieve retinopexy. Silicone oil is typically required. Theory suggests that endoresection reduces tumor-related ocular morbidity but adds the risk of vitreoretinal complications (silicone oil removal, secondary rhegmatogenous retinal detachment, intraocular hemorrhage) and tumor dissemination.⁵⁶

Trans-scleral Tumor Resection

Trans-scleral tumor resection (TSR) can be lamellar or full thickness. The more widely used partial thickness technique involves the preparation of a lamellar scleral flap, ocular decompression by limited pars plana vitrectomy, resection of the tumor together with the deep scleral lamella, suturing of the scleral flap, and intraocular injection of balanced salt solution. Due to initially high tumor regrowth rates, adjunctive radiotherapy has been added before or after TSR.⁵⁷

Primary indications for TSR include large anterior melanomas, where endoresection is not possible, and the ability to tolerate hypotensive anesthesia. Poor local control rates, coupled with a high incidence of post-operative complications (secondary rhegmatogenous retinal detachment, intraocular hemorrhage, ocular hypotony, and phthisis) and concerns about CM dissemination, have limited the widespread use of TSR.⁵⁸⁻⁶⁰ TSR can be considered a relatively high-risk alternative to enucleation of eyes with very large anteriorly placed CM.

Transpupillary Thermotherapy

In the 1950s, Dr Meyer-Schwickerath attempted primary treatment of CM with the xenon-arc laser.⁶¹ Since that time others have used argon, krypton, dye, and, most recently, the infrared spectrum. To date, no laser method has produced acceptable local control, but has added risks including hemorrhage, retinal detachment, edema and traction, scleromalacia with orbital tumor extension, and laser-induced optic neuropathy.

Transpupillary thermotherapy (TTT), as originally described by Oosterhuis and popularized by Shields,⁶²⁻⁶⁵ was suggested for the treatment of small tumors, up to 4 mm in height, lying near the optic disk or the fovea (in an effort to spare these structures from damage). With a modified delivery system beam widths between 1 and 3 mm and exposure times of up to one minute are typically generated.⁶⁶ This method was reported to offer a local tumor control rate of 76 % (not as successful as radiation therapy).⁶⁷ However, due to failures of local control (intraocular and orbital), TTT has largely been abandoned as a primary treatment for CM.⁶⁸ Current patient selection includes very thin tumors, treatment of circumpapillary tumors that cannot be reached by plaque, and the sandwich technique, where TTT is used in combination with a radiation plaque. At The New York Eye Cancer Center, we use TTT laser for marginal tumor recurrences and in patients who cannot tolerate plaque surgery.

Table 1: Outcomes of Radiation Therapy in Different Centers Regarding Vision, Tumor Recurrence, Metastasis, and Neovascular Glaucoma

Authors	Radiation	Study Group Size	Mean Dose (Gy)	Mean Follow-up (months)	Recurrence (%)	Secondary Enucleation (%)	Neovascular Glaucoma (%)	Metastasis (%)	Visual Acuity
Bergman et al. ⁶⁹	Ru-106	579	100	97	N/A	18	N/A	8 (5 years)	49 % better than 20/200 at 5 years
Fontanesi et al. ⁷⁰	I-125	144	79	46	2.3	9.7	5.5	5.5	41 % better than, or 20/200, at 3.9 years
Lommatzsch et al. ⁷¹	Ru-106	141	100	100	223	37 (15 years)	34 (15 years)	N/A	33 (15 years) 37 % better than 20/200 at 10 years
Gragoudas et al. ⁷²	Proton	128	70	64	3	6	N/A	20.5	42 % better than 20/200 at 5.3 years
Wilson et al. ⁷³	Proton	267	60	43	52	10.9	N/A	N/A	15 % better than 20/40
Char et al. ⁷⁴	Helium	21	70	110	5	22	35	18.6 (5 years)	33 % better than, or 20/200, at 10 years
Finger et al. ¹⁷	Pd-103	400	73	51	3	3.5	2.5	6 7.3 (5 years) 13.4 (10 years)	79 % better than, or 20/200, at 5 years 69 % better than, or 20/200, at 10 years
COMS ^{16,82}	I-125	657	≥85 Gy to 5 mm	60	10	13	N/A	10 (5 years) 18 (10 years)	57 % >20/200 at 3 years
Average	316	78	86	3	12	18			

Radiation Therapy for Choroidal Melanoma

You can destroy a choroidal melanoma with any form of radiation therapy, but dose-related differences (side effects) will be seen in the normal ocular structures. Therefore, our primary goal of destroying the tumor will be accomplished, but there will be distinct differences in resultant rates of visual acuity and eye preservation.

Teletherapy

Teletherapy means treatment from a distance. In ophthalmic oncology CM has been treated with cylindrically shaped beams of charged particles – protons or helium ions. Prior to treatment, tantalum clips are sewn to the episclera around the base of the tumor to localize the targeted zone. The particle-generating cyclotron is directed toward the eye in line with the CM as defined by the clips (see *Figure 4*). Eye movement is monitored on a screen and the beam turned off if the eye wanders. Typical daily fractions are 10–16 Gy, for five consecutive days (50–80 Gy). Each relatively high-dose-rate fraction is given during less than five minutes, compared with continuously over 5–7 days with brachytherapy. Therefore, in part due to high-dose-rate effects, the proton dose is much higher than numerically equivalent brachytherapy apex doses. Therefore, it is understandable that proton-beam local control rates are among the highest.^{49,75,76}

However, the cylindrically shaped beam must traverse the anterior segment to reach the CM. As Packer predicted, proton-beam-related anterior segment doses were relatively high, resulting in more reports of eyelash loss, dry eye, neovascularization of the iris, neovascular glaucoma, and cataract. These complications became even greater in treatment of large and anteriorly located tumors. Similarly, radiation retinopathy and optic neuropathy were more commonly reported in treatment of posteriorly located CM.⁴⁹

Brachytherapy

Brachytherapy means treatment up close. Stallard introduced the first ophthalmic plaques for the treatment of CM.¹⁴ The technique involves sewing the disk-shaped plaque device onto the sclera so as to cover the base of the intraocular tumor and a free margin (target zone).^{17,71,77–79} Radiation travels from the plaque through the sclera and into the CM. Radiation deposition is primarily governed by the inverse square law, Compton scattering, and absorption as it continues through the vitreous and exits through normal ocular structures. The original cobalt-60-based plaques produced high-energy gamma rays with greater irradiation of normal structures, the patient, and the surgeon. No longer in clinical use, cobalt-60 plaques were replaced with

ruthenium-106 plaques by Lommatzsch in East Germany, and by Packer, Rotman, and Sealy, who originally used iodine-125 plaques.^{79,81}

In 1985, the COMS chose to use iodine-125 seeds in standardized gold alloy plaques as the alternative treatment versus enucleation in the medium-sized CM trial. This decision made iodine-125 a clinical standard in North America for more than 16 years. In 1990, Finger realized that the lower-energy photons emitted from palladium-103 seeds would result in less irradiation of most normal ocular structures (and a greater likelihood of vision and eye preservation).^{81,82} Since that time, select centers have adopted palladium-103 plaque therapy. At The New York Eye Cancer Center, we suggest pre-operative comparative dosimetry (iodine-125, palladium-103, ruthenium-106) to monitor doses to critical intraocular structures (fovea, optic nerve, lens, opposite eye wall), prior to radionuclide selection for each plaque.¹⁷

It is important to note that iodine-125 and palladium-103 plaques deliver photons that can extend deeply into the eye. In contrast, ruthenium-106 plaques emit beta-particles that can only extend far enough to treat 5 mm high tumors reliably.^{22,25} Furthermore, the dose to the tumor base and tumor margin can be four times higher in treatment of the same 5 mm-tall CM using iodine-125 versus ruthenium-106. The high base dose will cause earlier chorioretinal atrophy.^{17,77,83} Like proton therapy, low-energy plaque irradiation of larger tumors has been associated with more radiation complications. However dry eye, eyelash loss and neovascular glaucoma are relatively uncommon (see *Table 1*).¹⁷

The most frequent low-energy plaque-related complications are radiation retinopathy, radiation optic neuropathy, and cataract.^{17,68-70} At The New York Eye Cancer Center, the largest CM basal dimension treated with ophthalmic plaque is 22 mm and the tallest has been 16 mm. Dr Finger's slotted plaques successfully control tumors that encircle the optic nerve (circumpapillary).⁷¹ Therefore, few patients cannot be treated with eye- and vision-conserving ophthalmic plaque radiation therapy.

Anti-Vascular Endothelial Growth Factor Therapy

Prior to the advent of bevacizumab and ranibizumab (Avastin® or Lucentis®, Roche-Genentech, South San Francisco, California, US), more than 50 % of patients were reported to have less than 20/200 vision five years after CM radiation therapy (see *Table 1*). Though this was all-cause visual morbidity, the most common causes of severe irreversible loss of vision were radiation maculopathy and radiation optic neuropathy. In 1997, Finger reported on short-term findings of reductions in retinal and optic nerve edema, as well as decreased retinal hemorrhage, associated with periodic intravitreal injections of bevacizumab. Later reports, and those of others, have supported these findings.⁸⁴⁻⁸⁶ It has been Finger's impression that higher radiation doses to fovea and optic nerve are harder to overcome with this method.

Conclusion

The primary goal of CM treatment is to destroy or remove the malignancy to prevent metastasis. Though enucleation and surgical resection are available, most patients are currently treated with plaque radiation therapy. The most widely used sources are iodine-125 and ruthenium-106 plaques, with a few referral centers using proton beam and palladium-103. Cyberknife and stereotactic radiosurgery are most exotic forms of EBRT and should be considered investigational. We know that all methods of radiation therapy can destroy a CM. However, evidence now exists that radiation dose to fovea, lens, and optic nerve can be used to predict rates of complications.^{81,82} Therefore, it is reasonable to compare the available radiation modalities, perform computer-aided simulations, calculate doses to critical structures, and choose the 'best' method prior to treatment.

Ophthalmic oncology has progressed from primary enucleation to modern and exotic methods of eye- and vision-sparing radiation therapy. Thankfully, in the modern era, fewer patients have to lose their eye due to the presence of CM. ■

- Pane AR, Hirst LW, Ultraviolet light exposure as a risk factor for ocular melanoma in Queensland, Australia, *Ophthalmic Epidemiol*, 2000;7:159-67.
- Bove R, Char DH, Nondiagnosed uveal melanomas, *Ophthalmology*, 2004;111:554-7.
- Chin K, Finger PT, Autofluorescence characteristics of suspicious choroidal nevi, *Optometry*, 2009;80:126-30.
- Edwards WC, Layden WE, Macdonald R, Jr., Fluorescein angiography of malignant melanoma of the choroid, *Am J Ophthalmol*, 1969;68:797-808.
- Lemke L, Jutte A, Scheibe A, [Differential diagnosis of malignant melanoma of the choroid with fluorescein], *Albrecht Von Graefes Arch Klin Exp Ophthalmol*, 1968;175:58-67.
- Du L, Xing Y, Chen C, Peng B, [Angiography characters changes of melanoma of choroid: a case report], *Yan Ke Xue Bao*, 2006;22:17-9.
- Guthoff R, Terwey B, Burk R, Von Domarus D, [Attempt at preoperative differentiation of malignant melanoma of the choroid. A comparison of nuclear magnetic resonance tomography, ultrasound echography and histopathology], *Klin Monbl Augenheilkd*, 1987;191:45-9.
- Wollensak J, Bende T, Seiler T, [Magnetic resonance tomography of choroid melanoma], *Fortschr Ophthalmol*, 1988;35:719-22.
- Seiler T, Bende T, Schilling A, Wollensak J, [Magnetic resonance tomography in ophthalmology. I. Choroid melanoma], *Klin Monbl Augenheilkd*, 1987;191:203-10.
- Finger PT, Chin K, Iacob CE, 18-Fluorine-labelled 2-deoxy-2-fluoro-D-glucose positron emission tomography/computed tomography standardised uptake values: a non-invasive biomarker for the risk of metastasis from choroidal melanoma. *Br J Ophthalmol* 2006;90:1263-6.
- Reddy S, Kurli M, Tena LB, Finger PT, PET/CT imaging: detection of choroidal melanoma, *Br J Ophthalmol*, 2005;89:1265-9.
- Finger PT, Kurli M, Reddy S, et al., Whole body PET/CT for initial staging of choroidal melanoma, *Br J Ophthalmol*, 2005;89:1270-4.
- Freudenberg LS, Schueleer AO, Beyer T, et al., Whole-body fluorine-18 fluorodeoxyglucose positron emission tomography/computed tomography (FDG-PET/CT) in staging of advanced uveal melanoma, *Surv Ophthalmol*, 2004;49:537-40.
- Stallard HB, Radiotherapy for malignant melanoma of the choroid, *Br J Ophthalmol*, 1966;50:147-55.
- Verschueren KM, Creutzberg CL, Schalijs-Delfos NE, et al., Long-term outcomes of eye-conserving treatment with Ruthenium(106) brachytherapy for choroidal melanoma, *Radiother Oncol*, 2010;95:332-8.
- Collaborative Ocular Melanoma Study Group, The COMS randomized trial of iodine 125 brachytherapy for choroidal melanoma: V. Twelve-year mortality rates and prognostic factors: COMS report No. 28, *Arch Ophthalmol*, 2006;124:1684-93.
- Finger PT, Chin KJ, Duvall G, Palladium-103 ophthalmic plaque radiation therapy for choroidal melanoma: 400 treated patients, *Ophthalmology*, 2009;116:790-6, 796 e1.
- Dendale R, Lumbroso-Le Rouic L, Noel G, et al., Proton beam radiotherapy for uveal melanoma: results of Curie Institut-Orsay proton therapy center (ICPO), *Int J Radiat Oncol Biol Phys*, 2006;65:780-7.
- Henderson MA, Shirazi H, Lo SS, et al., Stereotactic radiosurgery and fractionated stereotactic radiotherapy in the treatment of uveal melanoma, *Technol Cancer Res Treat*, 2006;5:411-9.
- Collaborative Ocular Melanoma Study Group, Factors predictive of growth and treatment of small choroidal melanoma: COMS Report No. 5, *Arch Ophthalmol*, 1997;115:1537-44.
- Margo CE, The Collaborative Ocular Melanoma Study: an overview, *Cancer Control*, 2004;11:304-9.
- Damato B, Detection of uveal melanoma by optometrists in the United Kingdom, *Ophthalmic Physiol Opt*, 2001;21:268-71.
- Radcliffe NM, Finger PT, Eye cancer related glaucoma: current concepts, *Surv Ophthalmol*, 2009;54:47-73.
- Shields CL, Furuta M, Berman EL, et al., Choroidal nevus transformation into melanoma: analysis of 2514 consecutive cases, *Arch Ophthalmol*, 2009;127:981-7.
- Damato B, Developments in the management of uveal melanoma, *Clin Experiment Ophthalmol*, 2004;32:639-47.
- Accuracy of diagnosis of choroidal melanomas in the Collaborative Ocular Melanoma Study. COMS report no. 1, *Arch Ophthalmol*, 1990;108:1268-73.
- Boldt HC, Melia BM, Liu JC, Reynolds SM, I-125 brachytherapy for choroidal melanoma photographic and angiographic abnormalities: the Collaborative Ocular Melanoma Study: COMS Report No. 30, *Ophthalmology*, 2009;116:106-15 e1.
- Shields CL, Bianciotto C, Pironidini C, et al., Autofluorescence of choroidal melanoma in 51 cases, *Br J Ophthalmol* 2008;92:617-22.
- Shields CL, Mashayekhi A, Materin MA, et al., Optical coherence tomography of choroidal nevus in 120 patients, *Retina*, 2005;25:243-52.
- Boldt HC, Byrne SF, Gilson MM, et al., Baseline echographic characteristics of tumors in eyes of patients enrolled in the Collaborative Ocular Melanoma Study: COMS report no. 29, *Ophthalmology*, 2008;115:1390-7, 1397 e1-2.
- Freyler H, Egerer I, Echography and histological studies in various eye conditions, *Arch Ophthalmol*, 1977;95:1387-94.
- Collaborative Ocular Melanoma Study Group, Mortality in patients with small choroidal melanoma. COMS report no. 4, *Arch Ophthalmol*, 1997;115:886-93.
- The Collaborative Ocular Melanoma Study (COMS) randomized trial of pre-enucleation radiation of large choroidal melanoma II: initial mortality findings. COMS report no. 10, *Am J Ophthalmol*, 1998;125:779-96.
- Diener-West M, Earle JD, Fine SL, et al., The COMS randomized trial of iodine 125 brachytherapy for choroidal melanoma,

- III: initial mortality findings. COMS Report No. 18, *Arch Ophthalmol*, 2001;119:969-82.
35. Finger PT, Chin KJ, [(18)F]Fluorodeoxyglucose Positron Emission Tomography/Computed Tomography (PET/CT) Physiologic Imaging of Choroidal Melanoma: Before and After Ophthalmic Plaque Radiation Therapy, *Int J Radiat Oncol Biol Phys*, 2011;79:137-42.
 36. Bechrakis NE, Foerster MH, Bornfeld N, Biopsy in indeterminate intraocular tumors, *Ophthalmology*, 2002;109:235-42.
 37. Horsman DE, Sroka H, Rootman J, White VA, Monosomy 3 and isochromosome 8q in a uveal melanoma, *Cancer Genet Cytogenet*, 1990;45:249-53.
 38. Prescher G, Bornfeld N, Hirsch H, et al., Prognostic implications of monosomy 3 in uveal melanoma, *Lancet*, 1996;347:1222-5.
 39. Onken MD, Worley LA, Ehlers JP, Harbour JW, Gene expression profiling in uveal melanoma reveals two molecular classes and predicts metastatic death, *Cancer Res*, 2004;64:7205-9.
 40. Kvantá A, Seregard S, Kopp ED, et al., Choroidal biopsies for intraocular tumors of indeterminate origin, *Am J Ophthalmol*, 2005;140:1002-6.
 41. McLean IW, Foster WD, Zimmerman LE, Gamel JW, Modifications of Callender's classification of uveal melanoma at the Armed Forces Institute of Pathology, *Am J Ophthalmol*, 1983;96:502-9.
 42. Seddon JM, Albert DM, Lavin PT, Robinson N, A prognostic factor study of disease-free interval and survival following enucleation for uveal melanoma, *Arch Ophthalmol*, 1983;101:1894-9.
 43. Gamel JW, McLean IW, Foster WD, Zimmerman LE, Uveal melanomas: correlation of cytologic features with prognosis, *Cancer*, 1978;41:1897-901.
 44. Lee CS, Cho A, Lee KS, Lee SC, Association of high metabolic activity measured by positron emission tomography imaging with poor prognosis of choroidal melanoma, *Br J Ophthalmol*, 2011;95(11):1588-91.
 45. Kujala E, Makitie T, Kivela T, Very long-term prognosis of patients with malignant uveal melanoma, *Invest Ophthalmol Vis Sci* 2003;44:4651-9.
 46. Eskelin S, Pyrhonen S, Summanen P, et al., Screening for metastatic malignant melanoma of the uvea revisited, *Cancer*, 1999;85:1151-9.
 47. Freton A, Chin KJ, Raut R, Initial PET/CT staging for choroidal melanoma: AJCC correlation and second nonocular primaries in 333 patients, *Eur J Ophthalmol*, 2011; [ePub ahead of print].
 48. Finger PT, The 7th edition AJCC staging system for eye cancer: an international language for ophthalmic oncology, *Arch Pathol Lab Med*, 2009;133:1197-8.
 49. Finger PT, Radiation therapy for choroidal melanoma, *Surv Ophthalmol*, 1997;42:215-32.
 50. Moshfeghi DM, Moshfeghi AA, Finger PT, Enucleation, *Surv Ophthalmol* 2000;44:277-301.
 51. Hawkins BS, The Collaborative Ocular Melanoma Study (COMS) randomized trial of pre-enucleation radiation of large choroidal melanoma: IV. Ten-year mortality findings and prognostic factors. COMS report number 24, *Am J Ophthalmol*, 2004;138:936-51.
 52. Zimmerman LE, McLean IW, Foster WD, Does enucleation of the eye containing a malignant melanoma prevent or accelerate the dissemination of tumour cells, *Br J Ophthalmol*, 1978;62:420-5.
 53. Blanco G, Diagnosis and treatment of orbital invasion in uveal melanoma, *Can J Ophthalmol*, 2004;39:388-96.
 54. Chin K, Margolin CB, Finger PT, Early ocular prosthesis insertion improves quality of life after enucleation, *Optometry*, 2006;77:71-5.
 55. Bechrakis NE, Hocht S, Martus P, et al., [Endoresection following proton beam irradiation of large uveal melanomas], *Ophthalmologe*, 2004;101:370-6.
 56. Bechrakis NE, Petousis V, Krause L, [Surgical treatment modalities in uveal melanomas], *Klin Monbl Augenheilkd*, 2009;226:921-6.
 57. Damato B, Adjuvant plaque radiotherapy after local resection of uveal melanoma, *Front Radiat Ther Oncol*, 1997;30:123-32.
 58. Damato BE, Paul J, Foulds WS, Risk factors for metastatic uveal melanoma after trans-scleral local resection, *Br J Ophthalmol*, 1996;80:109-16.
 59. Bechrakis NE, Petousis V, Willerding G, et al., Ten-year results of transscleral resection of large uveal melanomas: local tumour control and metastatic rate, *Br J Ophthalmol*, 2007;94:460-6.
 60. Puusaari I, Damato B, Kivela T, Transscleral local resection versus iodine brachytherapy for uveal melanomas that are large because of tumour height, *Graefes Arch Clin Exp Ophthalmol*, 2007;245:522-33.
 61. Meyer-Schwickerath G, *Lichtkoagulation*, Stuttgart: Ferdinand Enke Verlag, 1959.
 62. Journee-de Korver JG, Oosterhuis JA, Kakebeeke-Kemme HM, de Wolff-Rouendaal D, Transpupillary thermotherapy (TTT) by infrared irradiation of choroidal melanoma, *Doc Ophthalmol*, 1992;82(3):185-91.
 63. Oosterhuis JA, Journee-de Korver HG, Kakebeeke-Kemme HM, Bleeker JC, Transpupillary thermotherapy in choroidal melanomas, *Arch Ophthalmol*, 1995;113(3):315-21.
 64. Shields CL, Shields JA, Cater J, et al., Transpupillary thermotherapy for choroidal melanoma: tumor control and visual results in 100 consecutive cases, *Ophthalmology*, 1998;105(4):581-90.
 65. Shields CL, Shields JA, DePotter P, Khetarpal S, Transpupillary thermotherapy in the management of choroidal melanoma, *Ophthalmology*, 1996;103(10):1642-50.
 66. Gruterich M, Mueller AJ, Ulbig M, Kampik A, [What is the value of transpupillary thermotherapy in treatment of flat posterior choroid melanomas? A systematic review of the literature?], *Klin Monbl Augenheilkd*, 1999;215:147-51.
 67. Aaberg TM, Jr, Bergstrom CS, Hickner ZJ, Lynn MJ, Long-term results of primary transpupillary thermal therapy for the treatment of choroidal malignant melanoma, *Br J Ophthalmol*, 2008;92:741-6.
 68. Finger PT, Lipka AC, Lipkowitz JL, et al., Failure of transpupillary thermotherapy (TTT) for choroidal melanoma: two cases with histopathological correlation, *Br J Ophthalmol*, 2000;84:1075-6.
 69. Bergman L, Nilsson B, Lundell G, et al., Ruthenium brachytherapy for uveal melanoma, 1979-2003: survival and functional outcomes in the Swedish population. *Ophthalmology*, 2005;112(5):834-40.
 70. Fontanesi J, Meyer D, Xu S, Tai D, Treatment of choroidal melanoma with I-125 plaque, *Int J Radiat Oncol Biol Phys*, 1993;26(4):619-23.
 71. Lommatzsch PK, Werschnik C, Schuster E, Long-term follow-up of Ru-106/Rh-106 brachytherapy for posterior uveal melanoma, *Graefes Arch Clin Exp Ophthalmol*, 2000;238:129-37.
 72. Gragoudas ES, Seddon JM, Egan K, et al., Long-term results of proton beam irradiated uveal melanomas, *Ophthalmology*, 1987;94(4):349-53.
 73. Wilson MW, Hungerford JL, Comparison of episcleral plaque and proton beam radiation therapy for the treatment of choroidal melanoma, *Ophthalmology*, 1999;106(8):1579-87.
 74. Char DH, Kroll SM, Castro J, Ten-year follow-up of helium ion therapy for uveal melanoma, *Am J Ophthalmol*, 1998;125(1):81-9.
 75. Hocht S, Bechrakis NE, Nausner M, et al., Proton therapy of uveal melanomas in Berlin. 5 years of experience at the Hahn-Meitner Institute, *Strahlenther Onkol*, 2004;180:419-24.
 76. Gragoudas ES, Lane AM, Munzenrider J, et al., Long-term risk of local failure after proton therapy for choroidal/ciliary body melanoma, *Trans Am Ophthalmol Soc*, 2002;100:43-8; discussion 48-9.
 77. Shields CL, Shields JA, Cater J, et al., Plaque radiotherapy for uveal melanoma: long-term visual outcome in 1106 consecutive patients, *Arch Ophthalmol*, 2000;118:1219-28.
 78. Finger PT, Finger's "slotted" eye plaque for radiation therapy: treatment of juxtapapillary and circumpapillary intraocular tumours, *Br J Ophthalmol*, 2007;91:891-4.
 79. Finger PT, Buffa A, Mishra S, et al., Palladium 103 plaque radiotherapy for uveal melanoma. Clinical experience, *Ophthalmology*, 1994;101:256-63.
 80. Packer S, Rotman M, Fairchild RG, et al., Irradiation of choroidal melanoma with iodine 125 ophthalmic plaque, *Arch Ophthalmol* 1980;98:1453-7.
 81. Finger PT, Chin KJ, Yu GP, Patel NS, Risk Factors for Cataract After Palladium-103 Ophthalmic Plaque Radiation Therapy, *Int J Radiat Oncol Biol Phys*, 2011;80(3):800-6.
 82. Finger PT, Chin KJ, Yu GP, Risk factors for radiation maculopathy after ophthalmic plaque radiation for choroidal melanoma, *Am J Ophthalmol*, 2010;149:608-15.
 83. Jampol LM, Moy CS, Murray TG, et al., The COMS randomized trial of iodine 125 brachytherapy for choroidal melanoma: IV. Local treatment failure and enucleation in the first 5 years after brachytherapy. COMS report no. 19, *Ophthalmology*, 2002;109:2197-206.
 84. Finger PT, Anti-VEGF bevacizumab (Avastin) for radiation optic neuropathy, *Am J Ophthalmol*, 2007;143:335-8.
 85. Finger PT, Radiation retinopathy is treatable with anti-vascular endothelial growth factor bevacizumab (Avastin), *Int J Radiat Oncol Biol Phys*, 2008;70:974-7.
 86. Gupta A, Muecke JS, Treatment of radiation maculopathy with intravitreal injection of bevacizumab (Avastin), *Retina*, 2008;28:964-8.

Win an iPad 2!



Register by 31 March
to enter the 9GA
prize draw

www.9ga.iapb.org/registration

Photo courtesy LV Prasad Eye Institute

www.9ga.iapb.org



IAPB 9TH GENERAL ASSEMBLY 2012

**17-20 SEPTEMBER
HYDERABAD, INDIA**

GLOBAL SPONSORS AND SUPPORTERS

 Brien Holden Vision Institute

 **cbm**
together we can do more

 MECTIZAN[®]
DONATION
PROGRAM

INTERNATIONAL SPONSORS AND SUPPORTERS

OPTOMETRYGIVINGSTIGHT
Transforming lives through the gift of vision

 ZEISS

 sightandlife

REGIONAL SPONSORS AND SUPPORTERS

 APPASAMY
ASSOCIATES
Empowering Vision[®]

 essilor

 LIONS
CLUBS

 ORBIS
using eyes worldwide

 Sightsavers

Eye Health: Everyone's Business

Hyderabad, India, 17-20 September 2012

The premier global event discussing public health topics related to blindness and vision impairment

- **Join** 1,000+ health professionals
- **Listen** to world-leading experts discuss effective aid for eye health and development
- **Share** new ideas and latest research – together we can put eye health on everybody's agenda

**Abstracts invited on a range of eye health topics.
Register by 31 March for an early-bird discount!**

INTERNATIONAL AGENCY FOR THE
PREVENTION OF BLINDNESS

Charity registered in
England and Wales No. 1100559



ORGANISING PARTNER
LV PRASAD
EYE INSTITUTE

TOUCHOPHTHALMOLOGY.COM

SUPPORTING THE OPHTHALMIC COMMUNITY

Touchophthalmology.com showcases articles from leading review journals *European Ophthalmic Review* and *US Ophthalmic Review*, alongside content from other highly respected institutions and authorities.

Through the dissemination of leading opinion and best practice, touchophthalmology.com aims to assist ophthalmologists and healthcare administrators in continuously developing their knowledge, effectiveness, and productivity.

- Contributions from leading voices in ophthalmic medicine
- Timely comment and practice guidelines
- Comprehensive review and original research
- Event planners and symposium reviews
- Latest news and press releases
- Journal archive



interface; 0.1% (1/844) had foreign body sensation; 0.2% (2/844) had pain; and 0.7% (6/844) had ghosting or double images in the operative eye. The following complications did NOT occur 3 months following LASIK in this clinical trial: corneal edema and need for lifting and/or resecting the flap/cap.

Adverse Events and Complications for Hyperopia: Certain adverse events and complications occurred after the LASIK surgery. Only one adverse event occurred during the clinical study: one eye (0.4%) had a retinal detachment or retinal vascular accident reported at the 3 month examination. The following adverse events did NOT occur: corneal infiltrate or ulcer requiring treatment; lost, misplaced, or misaligned flap, or any flap/cap problems requiring surgical intervention beyond 1 month; corneal edema at 1 month or later visible in the slit lamp exam; any complication leading to intraocular surgery; melting of the flap of > 1 mm²; epithelium of > 1 mm² in the interface with loss of 2 lines or more of BSCVA; uncontrolled IOP rise with increase of > 5 mmHg or any reading above 25 mmHg and decrease in BSCVA of > 10 letters not due to irregular astigmatism as shown by hard contact lens refraction.

The following complications occurred 6 months after LASIK during this clinical trial: 0.8% (2/262) of eyes had a corneal epithelial defect and 0.8% (2/262) had any epithelium in the interface.

The following complications did NOT occur 6 months following LASIK in this clinical trial: corneal edema; foreign body sensation; pain, ghosting or double images; and need for lifting and/or resecting of the flap/cap.

Adverse Events and Complications for Mixed Astigmatism: Certain adverse events and complications occurred after the LASIK surgery. No protocol defined adverse events occurred during the clinical study. However, two events occurred which were reported to the FDA as Adverse Events. The first event involved a patient who postoperatively was subject to blunt trauma to the treatment eye 6 days after surgery. The patient was found to have an intact globe with no rupture, inflammation or any dislodgement of the flap. The second event involved the treatment of an incorrect axis of astigmatism which required retreatment.

The following adverse events did NOT occur: corneal infiltrate or ulcer requiring treatment; corneal epithelial defect involving the keratectomy at 1 month or later; corneal edema at 1 month or later visible in the slit lamp exam; epithelium of > 1 mm² in the interface with loss of 2 lines or more of BSCVA; lost, misplaced, or misaligned flap, or any flap/cap problems requiring surgical intervention beyond 1 month; decrease in BSCVA of > 10 letters not due to irregular astigmatism as shown by hard contact lens refraction; any complication leading to intraocular surgery; melting of the flap of > 1 mm²; uncontrolled IOP rise and retinal detachment or retinal vascular accident.

None of the following complications occurred at 3 months after LASIK during this clinical trial: corneal edema; corneal epithelial defect; any epithelium in the interface; foreign body sensation, pain, ghosting or double images; and need for lifting and/or resecting of the flap/cap.

Subjects were asked to complete a patient questionnaire preoperatively and at 3-months, 6-months, and 1-year postoperatively.

Adverse Events and Complications for Wavefront - guided Myopia:

Certain adverse events and complications occurred after the wavefront-guided LASIK surgery. No adverse event occurred during wavefront-guided treatments during this clinical study.

The following adverse events did NOT occur: corneal infiltrate or ulcer requiring treatment; lost, misplaced or misaligned flap or any flap/cap problems requiring surgical intervention beyond 1 month; corneal edema at 1 month or later visible in the slit lamp exam; any complication leading to intraocular surgery; melting of the flap of > 1 mm²; epithelium of > 1 mm² in the interface with loss of 2 lines or more of BSCVA; uncontrolled IOP rise with increase of > 5 mmHg or any reading above 25 mmHg; and decrease in BSCVA of > 10 letters not due to irregular astigmatism as shown by hard contact lens refraction.

The following complications occurred 3 months after wavefront-guided LASIK during this clinical trial: corneal epithelial defect (0.6%); foreign body sensation (0.6%); and pain (0.6%).

The following complications did NOT occur 3 months following wavefront-guided LASIK in this clinical trial: corneal edema; any epithelium in the interface; ghosting or double images; and need for lifting and/or resecting of the flap/cap.

ATTENTION: The safety and effectiveness of LASIK surgery has ONLY been established with an optical zone of 6.0 – 6.5 mm and an ablation zone of 9.0 mm.

Reference the Directions for Use labeling for a complete listing of indications, warnings and precautions.

1. Accutane® is a registered trademark of Hoffmann-La Roche Inc.
2. Cordarone® is a registered trademark of Sanofi S.A.
3. Imitrex® is a registered trademark of Glaxo Group Limited

US OPHTHALMIC REVIEW

Call for Submissions



Call for submissions

US Ophthalmic Review endeavors to support ophthalmologists in their daily practice through peer-reviewed content, including original contributions, commentaries, review articles and case studies. The journal provides comprehensive discussion and analysis of the latest medical advances and therapeutic options available to ophthalmologists to help diagnose, treat and achieve better patient prognoses.

Join the debate

With a focus on all aspects of ophthalmology, including practice management and policy, *US Ophthalmic Review* is always keen to hear from leading authorities wishing to discuss potential submissions and will give due consideration to all manuscripts submitted.

Manuscripts can be submitted to the journal's Editor, Misty Gilbert. To download the 'Instructions to Authors' information, please visit www.touchophthalmology.com

US Ophthalmic Review Touch Briefings

Saffron House, 6–10 Kirby Street,
London EC1N 8TS, UK

**For further information,
please contact Misty Gilbert**

T: +44 (0) 20 7452 5357

E: misty.gilbert@touchbriefings.com





Health Care Professional Information Sheet-All WaveLight[®] Allegretto Wave[®] System Indications

The WaveLight[®] ALLEGRETTO WAVE[®] / ALLEGRETTO WAVE[®] Eye-Q Excimer Laser System

CAUTION: Federal (USA) law restricts this device to sale by, or on the order of a physician.

Statements regarding the potential benefits of wavefront-guided and Wavefront Optimized[®] laser-assisted in-situ keratomileusis (LASIK) are based upon the results of clinical trials. These results are indicative of not only the WaveLight[®] ALLEGRETTO WAVE[®] / ALLEGRETTO WAVE[®] Eye-Q Excimer Laser System treatment but also the care of the clinical physicians, the control of the surgical environment by those physicians, the clinical trials' treatment parameters and the clinical trials' patient inclusion and exclusion criteria. Although many clinical trial patients after the wavefront-guided and Wavefront Optimized[®] procedure saw 20/20 or better and/or had or reported having better vision during the day and at night, compared to their vision with glasses or contact lenses before the procedure, individual results may vary. You can find information about the clinical trials below and in the Procedure Manuals for the WaveLight[®] ALLEGRETTO WAVE[®] / ALLEGRETTO WAVE[®] Eye-Q Excimer Laser System.

As with any surgical procedure, there are risks associated with the wavefront-guided and Wavefront Optimized[®] treatment. Before treating patients with these procedures, you should carefully review the Procedure Manuals, complete the Physician WaveLight[®] System Certification Course, provide your patients with the Patient Information Booklet, and discuss the risks associated with this procedure and questions about the procedure with your patients.

INDICATIONS: The WaveLight[®] ALLEGRETTO WAVE[®] / ALLEGRETTO WAVE[®] Eye-Q Excimer Laser System is indicated to perform LASIK treatments in patients with documented evidence of a stable manifest refraction defined as less than or equal to 0.50 diopters (D) of preoperative spherical equivalent shift over one year prior to surgery, exclusive of changes due to unmasking latent hyperopia in patients 18 years of age or older: for the reduction or elimination of myopic refractive errors up to -12.0 D of sphere with and without astigmatic refractive errors up to -6.0 D; for the reduction or elimination of hyperopic refractive errors up to +6.0 D of sphere with and without astigmatic refractive errors up to 5.0 D at the spectacle plane, with a maximum manifest refraction spherical equivalent (MRSE) of +6.0 D; and in patients 21 years of age or older for the reduction or elimination of naturally occurring mixed astigmatism of up to 6.0 D at the spectacle plane.

LASIK is an elective procedure with the alternatives including but not limited to eyeglasses, contact lenses, photorefractive keratectomy (PRK), and other refractive surgeries. Only practitioners who are experienced in the medical management and surgical treatment of the cornea, who have been trained in laser refractive surgery including laser system calibration and operation, may use the device as approved. Prospective patients, as soon as they express an interest in an indicated LASIK procedure and prior to undergoing surgery, must be given the WaveLight[®] System Patient Information Booklet and must be informed of the alternatives for refractive correction including eyeglasses, contact lenses, PRK, and other refractive surgeries.

Clinical Data Myopia: The WaveLight[®] ALLEGRETTO WAVE[®] / ALLEGRETTO WAVE[®] Eye-Q Excimer Laser System for LASIK treatments of myopic refractive errors up to -12.0 D of sphere with and without astigmatic refractive errors up to -6.0 D at the spectacle plane was studied in clinical trials in the United States with 901 eyes treated, of which 813 of 866 eligible eyes were followed for 12 months. Accountability at 3 months was 93.8%, at 6 months was 91.9%, and at 12 months was 93.9%. The studies found that of the 844 eyes eligible for the uncorrected visual acuity (UCVA) analysis of effectiveness at the 3-month stability time point, 98.0% were corrected to 20/40 or better, and 84.4% were corrected to 20/20 or better without spectacles or contact lenses.

The clinical trials showed that the following subjective patient adverse events were reported as moderate to severe at a level at least 1% higher than baseline of the subjects at 3 months post-treatment: visual fluctuations (12.8% at baseline versus 28.6% at 3 months). Long term risks of LASIK for myopia with and without astigmatism beyond 12 months have not been studied.

Clinical Data Hyperopia: The WaveLight[®] ALLEGRETTO WAVE[®] / ALLEGRETTO WAVE[®] Eye-Q Excimer Laser System for

LASIK treatments of hyperopic refractive errors up to +6.0 D of sphere with and without astigmatic refractive errors up to 5.0 D with a maximum MRSE of +6.0 D has been studied in clinical trials in the United States with 290 eyes treated, of which 100 of 290 eligible eyes were followed for 12 months. Accountability at 3 months was 95.2%, at 6 months was 93.9%, and at 12 months was 69.9%.

The studies found that of the 212 eyes eligible for the UCVA analysis of effectiveness at the 6-month stability time point, 95.3% were corrected to 20/40 or better, and 67.5% were corrected to 20/20 or better without spectacles or contact lenses.

The study showed that the following subjective patient adverse events were reported as much worse by at least 1% of the subjects (in order of increasing frequency) at 6 months post final treatment: glare from bright lights (3.0%); night driving glare (4.2%); light sensitivity (4.9%); visual fluctuations (6.1%); and halos (6.4%). Long term risks of LASIK for hyperopia with and without astigmatism beyond 12 months have not been studied.

Clinical Data Mixed Astigmatism: The WaveLight[®] ALLEGRETTO WAVE[®] / ALLEGRETTO WAVE[®] Eye-Q Excimer Laser System for LASIK treatments of naturally occurring mixed astigmatism of up to 6.0 D at the spectacle plane has been studied in clinical trials in the United States with 162 eyes treated, of which 111 were eligible to be followed at 6 months. Accountability at 1 month was 99.4%, at 3 months was 96.0%, and at 6 months was 100.0%.

The studies found that of the 142 eyes eligible for the UCVA analysis of effectiveness at the 3-month stability time point, 95.8% achieved acuity of 20/40 or better, and 67.6% achieved acuity of 20/20 or better without spectacles or contact lenses. The clinical trials showed that the following subjective patient adverse events were reported as moderate to severe at a level at least 1% higher than baseline of the subjects at 3 months post-treatment: sensitivity to light (43.3% at baseline versus 52.9% at 3 months); visual fluctuations (32.1% at baseline versus 43.0% at 3 months); and halos (37.0% at baseline versus 42.3% at 3 months). Long term risks of LASIK for mixed astigmatism beyond 6 months have not been studied.

Clinical Data Wavefront-guided Treatment of Myopia: The WaveLight[®] ALLEGRETTO WAVE[®] / ALLEGRETTO WAVE[®] Eye-Q Excimer Laser System used in conjunction with the WaveLight[®] ALLEGRO Analyzer[®] device. The device uses a 6.5 mm optical zone, a 9.0 mm ablation/treatment zone, and is indicated for wavefront-guided LASIK: 1) for the reduction or elimination of up to -7.0 D of spherical equivalent myopia or myopia with astigmatism, with up to -7.0 D of spherical component and up to 3.0 D of astigmatic component at the spectacle plane; 2) in patients who are 18 years of age or older; and 3) in patients with documentation of a stable manifest refraction defined as ≤ 0.50 D of preoperative spherical equivalent shift over one year prior to surgery was studied in a randomized clinical trial in the United States with 374 eyes treated; 188 with wavefront-guided LASIK (Study Cohort) and 186 with Wavefront Optimized[®] LASIK (Control Cohort). 178 of the Study Cohort and 180 of the Control Cohort were eligible to be followed at 6 months. In the Study Cohort, accountability at 1 month was 96.8%, at 3 months was 96.8%, and at 6 months was 93.3%. In the Control Cohort, accountability at 1 month was 94.6%, at 3 months was 94.6%, and at 6 months was 92.2%.

The studies found that of the 180 eyes eligible for the UCVA analysis of effectiveness at the 6-month stability time point in the Study Cohort, 99.4% were corrected to 20/40 or better, and 93.4% were corrected to 20/20 or better without spectacles or contact lenses. In the Control Cohort, of the 176 eyes eligible for the UCVA analysis of effectiveness at the 6-month stability time point, 99.4% were corrected to 20/40 or better, and 92.8% were corrected to 20/20 or better without spectacles or contact lenses.

The clinical trials showed that the following subjective patient adverse events were reported as moderate to severe at a level at least 1% higher than baseline of the subjects at 3 months post-treatment in the Study Cohort: light sensitivity (37.2% at baseline versus 47.8% at 3 months); and visual fluctuations (13.8% at baseline versus 20.0% at 3 months). In the Control Cohort: halos (36.6% at baseline versus 45.4% at 3 months); and visual fluctuations (18.3% at baseline versus 21.9% at 3 months). Long term risks of wavefront-guided LASIK for myopia with and without astigmatism beyond 6 months have not been studied.

CONTRAINDICATIONS: LASIK treatments using the WaveLight[®] ALLEGRETTO WAVE[®] / ALLEGRETTO WAVE[®] Eye-Q Excimer Laser System are contraindicated if any of the following conditions exist. Potential contraindications are not limited to those included in this list: pregnant or nursing women; patients with a diagnosed collagen vascular,

autoimmune or immunodeficiency disease; patients with diagnosed keratoconus or any clinical pictures suggestive of keratoconus; and patients who are taking one or both of the following medications: isotretinoin (Accutane[®] 1), amiodarone hydrochloride (Cordarone[®] 2).

WARNINGS: Any LASIK treatment with the WaveLight[®] ALLEGRETTO WAVE[®] / ALLEGRETTO WAVE[®] Eye-Q Excimer Laser System is not recommended in patients who have: systemic diseases likely to affect wound healing, such as connective tissue disease, insulin dependent diabetes, severe atopic disease or an immunocompromised status; a history of Herpes simplex or Herpes zoster keratitis; significant dry eye that is unresponsive to treatment; severe allergies; and unreliable preoperative wavefront examination that precludes wavefront-guided treatment. The wavefront-guided LASIK procedure requires accurate and reliable data from the wavefront examination. Every step of every wavefront measurement that may be used as the basis for a wavefront-guided LASIK procedure must be validated by the user. Inaccurate or unreliable data from the wavefront examination will lead to an inaccurate treatment.

PRECAUTIONS: Safety and effectiveness of the WaveLight[®] ALLEGRETTO WAVE[®] / ALLEGRETTO WAVE[®] Eye-Q Excimer Laser System have not been established for patients with: progressive myopia, hyperopia, astigmatism and/or mixed astigmatism; ocular disease; previous corneal or intraocular surgery, or trauma in the ablation zone; corneal abnormalities including, but not limited to, scars, irregular astigmatism and corneal warpage; residual corneal thickness after ablation of less than 250 microns increasing the risk for corneal ectasia; pupil size below 7.0 mm after mydriatics where applied for wavefront-guided ablation planning; history of glaucoma or ocular hypertension of > 23 mmHg; taking the medication sumatriptan succinate (Imitrex[®] 3); under 18 years (21 years for mixed astigmatism) of age; over the long term (more than 12 months after surgery); corneal, lens and/or vitreous opacities including, but not limited to, cataract; iris problems including, but not limited to, coloboma and previous iris surgery compromising proper eye tracking; taking medications likely to affect wound healing including, but not limited to, antimetabolites; treatments with an optical zone below 6.0 mm or above 6.5 mm in diameter; treatment targets different from emmetropia (plano) in which the wavefront-calculated defocus (spherical term) has been adjusted; myopia greater than -12.0 D or astigmatism greater than 6 D; hyperopia greater than +6.0 D or astigmatism greater than 5.0 D; mixed astigmatism greater than +6.0 D; and in cylinder amounts > 4.0 to < 6.0 D.

Due to the lack of large numbers of patients in the general population, there are few subjects with cylinder amounts in this range to be studied. Not all complications, adverse events, and levels of effectiveness may have been determined.

Pupil sizes should be evaluated under mesopic illumination conditions. Effects of treatment on vision under poor illumination cannot be predicted prior to surgery. Some patients may find it more difficult to see in such conditions as very dim light, rain, fog, snow and glare from bright lights. This has been shown to occur more frequently in the presence of residual refractive error and perhaps in patients with pupil sizes larger than the optical zone size.

The refraction is determined in the spectacle plane, but treated in the corneal plane. In order to determine the right treatment program to achieve the right correction, assessment of the vertex distance during refraction testing is recommended. Preoperative evaluation for dry eyes should be performed. Patients should be advised of the potential for dry eyes post LASIK and post wavefront-guided LASIK surgery. This treatment can only be provided by a licensed healthcare professional.

Adverse Events and Complications for Myopia: Certain adverse events and complications occurred after the LASIK surgery. Two adverse events occurred during the postoperative period of the clinical study: 0.2% (2/876) had a lost, misplaced, or misaligned flap reported at the 1 month examination.

The following adverse events did NOT occur: corneal infiltrate or ulcer requiring treatment, corneal edema at 1 month or later visible in the slit lamp exam; any complication leading to intraocular surgery; melting of the flap of > 1 mm²; epithelium of > 1 mm² in the interface with loss of > 2 lines or more of BSCVA; uncontrolled IOP rise with increase of > 5 mmHg or any reading above 25 mmHg; retinal detachment or retinal vascular accident; and decrease in BSCVA of > 10 letters not due to irregular astigmatism as shown by hard contact lens refraction.

The following complications occurred 3 months after LASIK during this clinical trial: 0.8% (7/844) of eyes had a corneal epithelial defect; 0.1% (1/844) had any epithelium in the

Get there at the speed of WaveLight®.



The cheetah's aerodynamic body and flexible spine allow it to reach speeds of up to 75 miles an hour.

Only the WaveLight® Workstation can keep up with today's rapidly changing technology needs.

Designed to accommodate your refractive technology goals now and into the future, the WaveLight® Workstation is the fastest way to get where you want to go.

- The 200 kHz FS200 Femtosecond Laser creates **custom flaps in only 6 seconds***
- The 400 Hz ALLEGRETTO WAVE® Eye-Q Laser enables **treatment times of only 1.7 seconds per diopter***
- Provides a broad range of **customized, patient-specific treatments**
- Its advanced platform offers expanding technologies for more **streamlined procedures**

To see how the WaveLight® Workstation can get you there faster, visit AlconSurgical.com.



WaveLight® FS200
Femtosecond Laser

ALLEGRETTO WAVE®
Eye-Q Excimer Laser



© 2011 Novartis 11/11 ALL11498JAD

*Treatment times are approximate.

For Important Safety Information and Full Directions for Use, Please Reference the WaveLight® ALLEGRETTO WAVE® Laser System Full Directions for Use on Adjacent Pages.

