

## Applications of Autologous Serum Eye Drops in Aniridic Keratopathy

José Santiago López-García

*Ophthalmology Service, Hospital Cruz Roja, Madrid*

### Abstract

Aniridia is an uncommon congenital bilateral disease that involves the cornea, anterior chamber, lens, retina and optic nerve. Corneal changes in aniridic keratopathy include recurrent erosions of corneal epithelium, tear film instability, chronic pain, corneal vascularisation, dry eye, progressive corneal opacification and blindness. The autologous serum contains a variety of growth factors, vitamins and immunoglobulins, some of which are in higher concentrations than in natural tears. The growth factors and protein found in the serum may help the proliferation, migration and adhesion of epithelial corneal cells. They are by nature non-allergenic and their biochemical and biomechanical properties are similar to those of normal tears. The ocular surface, including corneal impression cytology and tear film evaluation, of patients with congenital aniridia was studied prior to and after treatment with autologous serum eye drops.

### Keywords

Aniridia, aniridic keratopathy, autologous serum eye drops, ocular surface, impression cytology, epitheliotropic factors

**Disclosure:** The author has no conflicts of interest to declare.

**Received:** 25 February 2009 **Accepted:** 10 March 2009 **DOI:** 10.17925/EOR.2009.03.01.51

**Correspondence:** José Santiago López-García, Ophthalmology Service, Hospital Cruz Roja, Avenida Reina Victoria no. 26, 28003 Madrid, Spain. E: docsantilopez@hotmail.com

Aniridia is an uncommon congenital bilateral disease caused by mutation of the *PAX6* gene. It is an ocular disorder that involves the cornea, anterior chamber, lens, retina and optic nerve.<sup>1</sup> Although aniridic keratopathy has traditionally been attributed to limbal stem cell deficiency, current evidence based on clinical observations and animal models of aniridia suggests that the proliferative potential of limbal stem cells may not initially be affected and this corneal alteration may be related to an abnormality in the limbal stem cell microenvironment.<sup>2</sup> Corneal changes in aniridic keratopathy include recurrent erosions and ulcerations of corneal epithelium, tear film instability, dry eye, chronic pain, corneal vascularisation, progressive corneal opacification and blindness.<sup>3</sup>

Tears perform a vital role in maintaining the health of the corneal epithelium. They contain substances such as epidermal growth factor (EGF), fibronectin, basic fibroblast growth factor (bFGF), vitamin A and other neural growth factors that are thought to maintain epithelial health; however, in dry eye the lack of tear production results in the deprivation of these epitheliotropic factors. Tear film disorder and dry-eye syndrome have been reported in connection with congenital aniridia.<sup>4,5</sup>

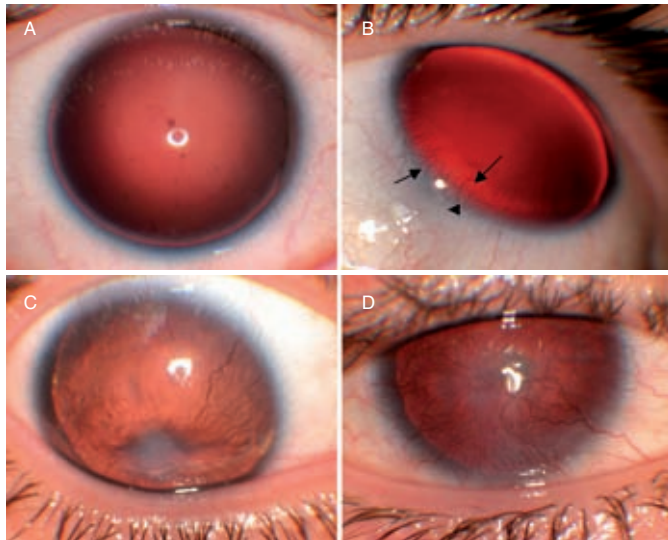
Serum is the fluid of blood devoid of its cellular components and clotting factors. It contains a variety of growth factors, vitamins and immunoglobulins, some of which are in higher concentrations than in natural tears. Autologous serum eye drops have been reported previously for the treatment of ocular surface diseases.<sup>6</sup> Autologous serum provides epitheliotropic factors such as EGF, bFGF, vitamin A, fibronectin,  $\alpha_2$  macroglobulin and neural growth factors that facilitate the proliferation, migration and adhesion of

epithelial corneal cells. By nature they are non-allergenic and their biochemical and biomechanical properties are similar to those of normal tears. Autologous serum facilitates mucin expression, which may contribute to the beneficial effects over the ocular surface in patients with dry eye.<sup>7</sup>

We think that the epitheliotropic factors present in autologous serum can help to treat the corneal changes that occur in patients with aniridia by a stem cell microenvironment improvement. With this purpose, a prospective study of 26 eyes from 13 patients (seven males and six females) with aniridic keratopathy before and after two months of autologous serum eye drops treatment was performed. The mean age of the patients was  $26 \pm 9.5$  years (range nine to 48 years). Patients undergoing topical treatment, except preservative-free tear substitutes, were excluded from the study. All patients underwent ophthalmic examinations, including visual acuity, biomicroscopy, intraocular pressure determination by Perkins' tonometry, ophthalmoscopy and, in some patients, ocular echography.

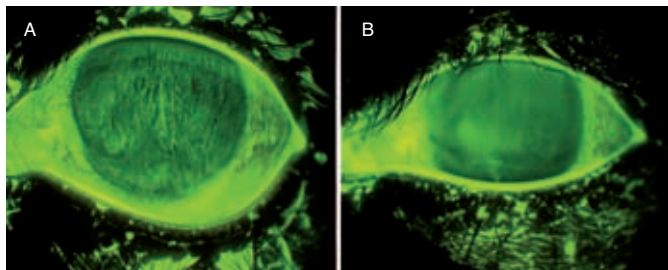
The ocular surface examinations included corneal impression cytology and tear film evaluation. For corneal cytology, strips of cellulose acetate filter paper (Millipore HAWP304) were applied after topical anaesthesia over the four corneal quadrants for a few seconds. The samples were processed and examined by light microscope. The criteria used for corneal cytology diagnosis were based on cellular shape and size, nuclear size, cytoplasmic staining, nuclear changes, nuclear–cytoplasmic (N:C) ratio and corneal conjunctivalisation. Corneal epithelial cells were graded according to the Murube and Rivas squamous metaplasia classification, which distinguishes several grades of squamous metaplasia with a range

**Figure 1: Classification of Patients**



A: Group A – the eyes do not show clinical keratopathy; B: Group B – the eyes show discontinuous areas of periphery vascular pannus (arrows); C: Group C – the eyes show vascular pannus that involves the total peripheral cornea and extends centrally, but does not affect the corneal central area; D – Group D: neovascular pannus and stromal opacity involve the corneal central area.

**Figure 2: Tear Film Stability**



Tear film stability determined by fluorescein stain before (A) and after (B) serum autologous eye drop treatment in a patient with moderate keratopathy (group C). Tear stability improved significantly after treatment.

between grades 0 and 5.<sup>8</sup> Tear film production and stability were evaluated by the break-up time (BUT) (normal, 10 seconds or more), Schirmer's test with anaesthesia (normal, 10mm/five minutes or more), tear meniscus level (normal, 0.5mm or more), rose bengal and fluorescein staining pattern of the cornea.

The eyes were divided into four groups according to the Mackman et al. classification.<sup>9</sup> The first group (A) consisted of five eyes without ocular clinical observation of keratopathy (stage 0 of Mackman et al. classification) (see *Figure 1A*). Group B comprised eight eyes with discontinuous areas of periphery vascular pannus (stage 1A) (see *Figure 1B*). Group C had seven eyes with vascular pannus that involved the total peripheral cornea and extended centrally but did not affect the central area of the cornea (stage 1B) (see *Figure 1C*). Finally, group D comprised six eyes with central corneal involvement by neovascular pannus and stromal opacity (stage 2) (see *Figure 1D*). Only patients treated with preservative-free artificial tears in the previous three months were included in the study. Slit-lamp exploration and ocular surface photography were used to evaluate the corneal surface and tear film before treatment and every two or three days until serum drops were stopped. An independent physician examined these photographs. Impression cytology was made prior to starting the serum eye drop treatment

and until a few days after treatment ended. Tear film production and stability were evaluated by the same physician (JSLG) two times during the study: prior to starting the serum eye drops and a few days after treatment ended.

For the autologous serum eye drop preparations, 40ml of blood was procured by venesection at the antecubital fossa with four vacuum extraction tubes without anticoagulants. The containers were left standing for two hours at room temperature in an upright position to allow complete clotting. The blood was then centrifuged at 3,000rpm for 10 minutes. The supernatant serum was removed under sterile

*We found that the autologous serum eye drops improved aniridic keratopathy in all patients, but especially in patients with slight or moderate severity.*

conditions in a laminar airflow hood. Two millilitres of serum were taken and deposited into sterile dropper bottles with 8ml of physiological serum for a final concentration of 20%. These bottles were labelled with the patient's identification and date of production, wrapped in aluminium paper and dispensed to the patients. Serum drops were applied eight times daily.

National clinical protocols and international norms were observed. This study was approved by the medical ethics committee of Ramón and Cajal Hospital. Each patient who agreed to participate had to sign his or her fully informed consent. Statistical analysis was carried out with a statistical package (SPSS 11.0 for Windows). Mean and standard deviations were used. Non-parametric tests were used to compare the groups before and after treatment. Differences were considered significant with a probability higher than 95% confidence interval (CI) ( $p < 0.05$ ).

Clinical manifestations, slit-lamp findings and corneal epithelial cell squamous metaplasia correlated to the severity of keratopathy. All patients showed a subjective improvement of keratopathy symptoms after the autologous serum applications, and there were no local side effects after this treatment.

Visual acuity improved slightly with the treatment. Corneal epithelialisation, epiphora, photophobia and foreign body sensation improved significantly with the treatment, mainly in group B and C eyes. Recurrent erosion is a frequent complication in patients with aniridic keratopathy. The frequency of recurrent episodes correlates with the severity of keratopathy. Corneal recurrent erosion episodes decreased substantially in all cases, but mainly in group B and C eyes. Autologous serum eye drop treatment has been published previously in the management of persistent epithelial defect. In this work, we found autologous serum therapy healed the persistent epithelial defect in five eyes and improved this defect in the other two eyes. In photographic sequences, we found a slight regression of vascular pannus and subepithelial scarring after treatment, but this was not significant, in particular in group D eyes. We think that this improvement is due to the beneficial effects of

autologous serum over the epithelial surface that diminished the inflammation and stimulation of the blood vessels.

Dry-eye severity was correlated with the keratopathy grade. In these patients, the aqueous layer produced by lacrimal glands did not change, as demonstrated by the normal Shirmer's test in all patients except the most severe eyes. By contrast, BUT was altered in practically all patients. This test measures tear stability, but it is a non-specific test that is altered in all dry-eye types. Autologous serum eye drop treatment significantly improved Schirmer and BUT levels in all patients. After the treatment, only eyes with severe keratopathy showed pathological levels in BUT and Schirmer's test. The autologous serum effect was more important in the BUT cohort because these levels were pathologically diminished in all eyes except group A. We think that the autologous serum effects on mucin expression, meibomian dysfunction and epithelial surface improved tear stability and BUT levels. The fluorescein stain also showed better tear stability and an increase in tear meniscus level after treatment with autologous serum (see *Figure 2*). Fluorescein and rose bengal staining patterns of the cornea improved after treatment.

The corneal epithelial cell squamous metaplasia obtained by impression cytology analysis correlated with keratopathy severity. Metaplasia was present in all patients in this study; even the group A eyes, without keratopathy symptoms, showed a grade 2 squamous metaplasia. Corneal conjunctivalisation, defined by goblet cell presence in corneal cytology, was common in group C and D eyes. The presence of goblet cells on the corneal surface is considered to provide clinical evidence of limbal stem cell deficiency. After two months of autologous serum eye drop treatment, the epithelial

squamous metaplasia improved significantly in all eyes, but in group D eyes the goblet cells remained after the treatment. These findings resulted in all of the patients showing a subjective clinical improvement after the autologous serum therapy in comparison with the prior treatment with artificial tears. All patients showed a subjective improvement in photophobia, epiphora and foreign body sensation after the treatment, except those in group A.

## Conclusion

Autologous serum has biochemical and biomechanical properties similar to those of normal tears, is non-allergenic and has antimicrobial and optic properties. It contains epitheliotrophic factors that are thought to be responsible for the therapeutic effect over ocular surface disorders. In this work, we found that the autologous serum eye drops improved aniridic keratopathy in all patients, but especially in patients with slight or moderate severity. In these patients, autologous serum eye drops were superior to conventional therapy with substitute tears in terms of improving ocular surface and subjective comfort. ■



José Santiago López-García works in the Ophthalmology Department of Cruz Roja Hospital in Madrid. His research activity has focused on clinical and histopathological studies of ocular surface disorders. He has published more than 50 articles, 17 of which are included on the Medline database. Dr López-García's reports have been published in *Ophthalmology*, *Cornea* and the *European Journal of Ophthalmology*. He is interested in the study of aniridic keratopathy as

indicative of primary limbal deficiency, and has written a doctoral thesis on aniridic keratopathy management. Dr López-García's aniridia research has twice been honoured by the Spanish Aniridia Association.

- Nelson LB, Spaeth GL, Nowinski TS, et al., Aniridia. A review, *Surv Ophthalmol*, 1984;28:621-42.
- Ramaesh K, Ramaesh T, Dutton GN, Dhillon B, Evolving concepts on the pathogenic mechanisms of aniridia related keratopathy, *Int J Biochem Cell Biol*, 2005;37:547-57.
- López-García JS, García Lozano I, Rivas L, Martínez Garchitorena J, Aniridic keratopathy management, *Arch Soc Esp Oftalmol*, 2006;81(8):435-44.
- Jastanciah S, Al-Rajhi AA, Association of aniridia and dry eyes, *Ophthalmology*, 2005;112:1535-40.
- Rivas L, Murube J, Rivas A, Murube E, Impression cytology study of dry eyes patients with congenital aniridia, *Arch Soc Esp Oftalmol*, 2003;78:615-22.
- Geerling G, MacLennan S, Hartwig D, Autologous serum eye drops for ocular surface disorders, *Br J Ophthalmol*, 2004;88:1467-74.
- López-García JS, García-Lozano I, Rivas L, Martínez-Garchitorena J, Autologous serum eye drops applications in Ophthalmology, *Arch Soc Esp Oftalmol*, 2007;82(1):9-20.
- Murube J, Rivas L, Impression cytology on conjunctiva and cornea in dry eye patients establishes a correlation between squamous metaplasia and dry eye clinical severity, *Eur J Ophthalmol*, 2003;13:115-27.
- Mackman G, Brightbill FS, Optiz AK, Corneal changes in aniridia, *Am J Ophthalmol*, 1979;87:497-502.

## Editor's Recommendation

### Autologous Serum Eye Drops for the Treatment of Dry Eye Diseases

Kojima T, Higuchi A, Goto E, Matsumoto Y, Dogru M, Tsubota K, *Cornea*, 2008;27(Suppl. 1):S25-30.

Conventional treatment of dry eye mainly consists of the use of preservative-free artificial eye drops and punctal occlusion. None of the commercially available artificial tear preparations includes essential tear components such as epidermal growth factor, hepatocyte growth factor, fibronectin, neurotrophic growth factor and vitamin A – all of which have been shown to play important roles in the maintenance of a healthy ocular surface epithelial milieu. We reported previously that autologous serum (AS) eye drops contain these essential factors and that AS eye drops are beneficial in the treatment of ocular surface diseases such as persistent epithelial defects, superior

limbic keratoconjunctivitis, keratoconjunctivitis sicca and neurotrophic keratopathy. However, there is some controversy regarding the efficacy of AS treatment. We demonstrated that this modality is more effective than artificial tears in a randomised controlled study. In *in vivo* and *in vitro* experiments, AS eye drops showed marked suppression of apoptosis in the conjunctival and corneal epithelium. Albumin, the major protein in serum, improved ocular surface damage *in vivo* and rescued apoptosis after serum deprivation *in vitro*. The biological background of AS eye drops and previous clinical studies of these medications for the treatment of dry eye are discussed. ■