

Redefining the Treatment Paradigm for Post-operative Inflammation Control – The Role of Topical Non-steroidal Anti-inflammatory Drugs

Oliver Findl

Associate Professor of Ophthalmology and Director of Department of Ophthalmology, Hanusch Krankenhaus, Vienna

Abstract

Topical ophthalmic non-steroidal anti-inflammatory drugs (NSAIDs) are used in the treatment of post-operative ocular inflammation and pain following cataract surgery and for some other clinical applications of ophthalmology, including cystoid macular oedema. Products vary by their pharmacological properties, clinical efficacy and tolerability, which affect their place in therapy for new agents in Europe. The pharmacological properties of topical ophthalmic NSAIDs and their place in current treatment of post-operative ocular inflammation are discussed in this article, focussing on bromfenac, which has been submitted for approval by the European Medicines Agency (EMA).

Keywords

Post-operative cataract surgery, ocular inflammation, ocular pain, cystoid macular oedema, non-steroidal anti-inflammatory drugs, bromfenac ophthalmic solution, prostaglandins inhibition

Disclosure: The author has no financial interest in any products mentioned. The author has been a scientific advisor to Croma Pharma.

Acknowledgement: Editorial assistance was provided by Touch Briefings.

Received: 27 August 2010 **Accepted:** 9 September 2010 **Citation:** *European Ophthalmic Review*, 2010;4:54–9 DOI: 10.17925/EOR.2010.04.01.54

Correspondence: Oliver Findl, Department of Ophthalmology, Hanusch Krankenhaus, Heinrich-Collin-Strasse 30, A-1140 Vienna, Austria. E: oliver@findl.at

Support: The publication of this article was funded by Bausch & Lomb Swiss Ag. The views and opinions expressed are those of the author and not necessarily those of Bausch & Lomb Swiss Ag.

Despite recent technical advances in cataract surgery, the physical trauma of ocular surgery is still enough to induce significant post-operative ocular inflammation. Inflammation is a major risk factor for complications after ocular surgery, including pain, visual fluctuation, delays in visual recovery and wound healing, elevated intraocular pressure (IOP) and cystoid macular oedema (CMO).^{1–4} The blood–aqueous barrier (BAB), consisting of the endothelium of iris blood vessels and non-pigmented ciliary epithelium, is particularly vulnerable to surgical trauma during cataract surgery. Damage caused to the BAB may resolve quickly or last for up to several months after surgery.⁵

Current treatment options available (both topical corticosteroids and topical ophthalmic non-steroidal anti-inflammatory drugs [NSAIDs]) aim to reduce prostaglandin (PG) production through inhibition of steps in the arachidonic cycle. PGs have multiple pharmacological effects, including the induction of miosis, increase in the permeability of the blood–ocular barriers, conjunctival hyperaemia and changes in IOP. PGs also have chemokinetic properties, mediate humoral and cellular phases of inflammatory responses and play a role in pain response and allergic reactions. Therefore, inhibition of their production using topical treatment, therefore, aims to reduce post-operative ocular inflammation and pain.

Topical corticosteroids have frequently been used for the treatment of inflammation post-ocular surgery; however, concerns over serious side effects with corticosteroids,^{6–8} including elevation of IOP,

progression of cataracts, increased risk of infection and worsening of corneal stromal melting have contributed to increased use of topical ophthalmic NSAIDs. NSAIDs appear to offer an improved risk/benefit balance with at least similar efficacy to the corticosteroids,^{2, 9–16} but without most of the side-effects associated with corticosteroids.^{17–22} This is because NSAIDs act at a later stage of the arachidonic acid cycle than do corticosteroids, resulting in more specific anti-inflammatory effects and fewer adverse events.¹²

Cyclooxygenases (COX) are involved in the inflammatory process. They catalyse the biosynthesis of eicosanoids from arachidonic acid to produce PGs. Although both COX-1 and COX-2 synthesise PGs, COX-2 may have important therapeutic implications in retinal diseases since it is the predominant isoform in human retinal pigment epithelium cells and is upregulated in response to pro-inflammatory cytokines.²³ The topical ophthalmic NSAIDs inhibit the COX-1 and/or COX-2 enzymes that catalyse the production of PGs; the more selective and potent the inhibition of COX-2, in particular, the lower the production of PGs, as well as the lower potential for side-effects.^{14,24,25} Since inhibition of COX occurs later in the arachidonic acid cycle, it is predicted to result in fewer adverse events with NSAIDs compared with corticosteroids.²⁶

Although refinement of surgical techniques has resulted in significantly shortened durations of post-operative flare, the presence of risk factors such as diabetes, uveitis or iris trauma may cause major disruption of the BAB after cataract surgery, prolonging patient rehabilitation.²⁷ Aqueous flare tends to be highest on the first day

after surgery, significantly declines until day 2 and continues to decline over the following months until pre-operative values are restored.²⁸ The protein content of the aqueous humour has been considered to arise mainly in the anterior chamber, leading to the hypothesis that dilution of aqueous in the anterior chamber may be the mechanism by which pupil dilation decreases aqueous flare.²⁹

Cooled intraocular irrigation reduces post-operative BAB disturbance after cataract surgery, but this effect is short-lived and may even prolong disturbance of BAB at a low intensity.²⁷ Various studies have reported reduction in aqueous flare following the application of tropicamide in normal patients, but only one study of the effect of mydriasis on aqueous flare in pseudophakic patients reported a decrease of 20% after three hours with a tropicamide and phenylephrine solution.³⁰ However, the relative reduction in flare after tropicamide pupil dilation in the pseudophakic eye has been shown to be similar to the reduction before surgery, making it unlikely that the decrease in flare after pupil dilation is a consequence of the dilution.²⁹ Other possible explanations for the reduction in flare could be the decrease in background scatter from the iris as a result of dilation³¹ or even the direct pharmacological effect of tropicamide.²⁹

BAB disturbance within the first 48 hours after small-incision cataract surgery differs significantly among patients and, in fact, may not even be detected during this timeframe. Studies in the future may elucidate the clinical relevance of acute flares and determine whether they can predict long-term BAB disturbance.³²

Treatment regimens for post-operative ocular inflammation are diverse, mainly because of the lack of good evidence-based comparisons between corticosteroids and NSAIDs, as well as a lack of information concerning protocol issues such as ideal treatment duration. Physicians currently tend to adopt their own style of treatment regimens based on little more than their clinical experience.

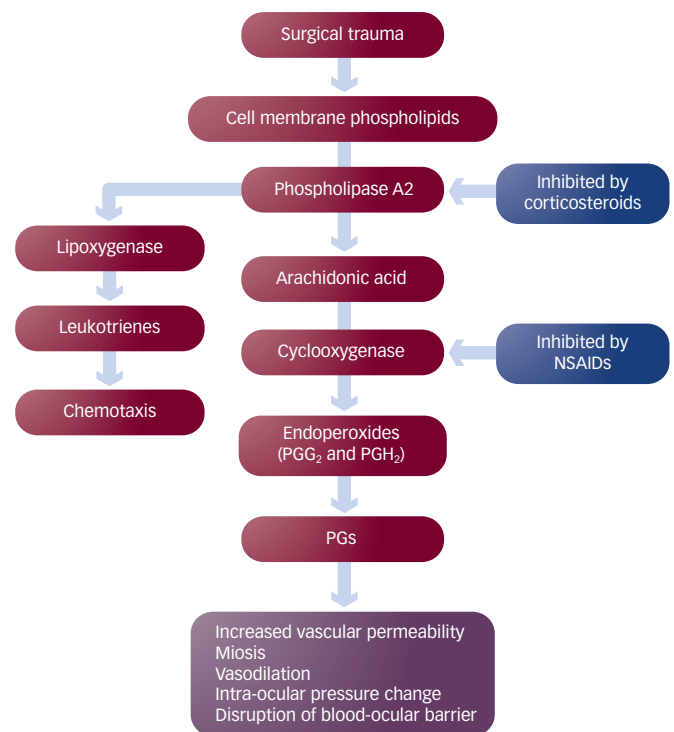
Several factors contribute to the issues of treatment protocols for post-operative ocular inflammation. For example, cataract surgery is a procedure that occurs mostly in elderly patients, a population in which compliance to medication is known to be poor. A treatment with eye-drops that have to be applied several times a day already presents a compliance problem, but can be particularly off-putting when associated with side effects such as stinging and burning, as is the case with eye drops for post-operative inflammation. A good rate of persistence and compliance to ophthalmic NSAID treatment is likely to result in improved efficacy. A faster recovery to pre-operative conditions would be expected to result in an improvement in the patient's quality of life.

Key Characteristics of an Ideal Topical Ophthalmic NSAID and Currently Approved NSAIDs

Ophthalmic NSAIDs play several critical roles in cataract surgery. Through their inhibition of PGs, they prevent intra-operative miosis, manage post-operative inflammation, prevent and treat CME, as well as reduce pain and discomfort following surgery (see *Figure 1*).³³

For the treatment of post-ocular inflammation and pain following cataract surgery, an ideal topical ophthalmic NSAID should have several features. The NSAID should penetrate efficiently into all ocular tissues to allow rapid and sustained achievement of therapeutic

Figure 1: Role of Non-steroidal Anti-inflammatory Drugs in Prostaglandin Inhibition



NSAID = non-steroidal anti-inflammatory drug; PG = prostaglandin. Source: Colin et al., 2007.⁴⁹

levels, which may facilitate early and prolonged control of post-operative ocular inflammation and pain. It should possess high potency of COX inhibition to enable sustained control of pain and inflammation with a reduced risk of side effects. Unlike orally ingested forms, topically applied NSAIDs inhibit PG synthesis because they reach high enough levels in the ocular tissues.⁹

Excessive intra-operative miosis is prevented by every commercially available topical NSAID,^{34,35} although the pharmacological effects on pupil size of these NSAIDs is varied, suggesting that PG-induced miosis and surgical technique are not the only contributory factors for surgically induced miosis.³⁶ Since decrease in pupil size is a risk factor for vitreous loss and zonular breaks in intraocular lens implantation during cataract surgery, the ability to prevent intra-operative miosis is an important clinical benefit.⁹

Post-operative ocular inflammation is partially caused by the release of PGs from uveal tissues, which may ultimately result in disruption of the blood-ocular barriers.³⁷ Activation of phospholipase A2 after tissue injury causes the breakdown of cell membrane phospholipids to arachidonic acid, which is then converted to PGs by COX or to hydroxyl acids and leukotrienes by 5-lipoxygenase.³⁴ This cascade of events affects multiple sites including the conjunctiva, sclera, cornea, aqueous humour, iris, ciliary body, choroids, retina, vitreous humour and optic nerve, which makes post-operative ocular inflammation a complex condition. Historically, prevention and treatment of ocular inflammation involved the use of topical corticosteroids due to their effect on COX and lipoxygenase pathways. However, more recently, the NSAIDs, bromfenac, diclofenac, ketorolac and nepafenac were approved by the FDA for the prevention and treatment of post-operative inflammation. Five topical ophthalmic NSAIDs (see *Table 1*), diclofenac, flurbiprofen, indomethacin, ketorolac and

Table 1: Dosing Schedules of Topical Ophthalmic Non-steroidal Anti-inflammatory Drugs Approved in Europe for the Treatment of Post-operative Ocular Inflammation and/or Pain

Generic Name	Dosing Schedule
Indomethacin	One drop 4–6 times per day 24 hours before surgery, 24 hours post-operatively until resolution of the symptoms
Ketorolac	One drop TID 24 hours before surgery, up to 3 weeks post-operatively
Nepafenac	One drop TID 30–120 minutes before surgery, first 2 weeks post-operatively, extended up to 3 weeks, as directed by the clinician
Diclofenac	One drop QID Up to 28 days post-operatively
Flurbiprofen	One drop QID Up to 28 days post-operatively

All the above-listed non-steroidal anti-inflammatory drugs are approved in Europe for the treatment of post-operative pain and inflammation, except flurbiprofen, which is not approved for post-operative pain. QID = four-times daily; TID = three-times daily. Source: Gaynes et al., 2008.¹³

Table 2: Proportion of Subjects with a Summed Ocular Inflammation Score Equal to Zero at Each Study Visit While on Monotherapy with Bromfenac

Study Day	Bromfenac (n = 356)	Placebo (n = 171)	p-value*
3	30 (8.4%)	2 (1.2%)	0.0012
8	124 (34.8%)	23 (13.5%)	<0.0001
15	211 (59.3%)	46 (26.9%)	<0.0001
22	234 (65.7%)	67 (39.2%)	<0.0001
29	285 (80.1%)	85 (49.7%)	<0.0001

Subjects who received a rescue medication are censored at the time of receipt of medication. The subject's last score before receipt of the medication is used for analysis.

*For bromfenac versus placebo and from the Cochran-Mantel-Haenszel test. Source: Donnenfeld et al., 2007.²⁶

nepafenac, are approved in Europe for the management of post-operative inflammation, pain or both.

Although they are approved specifically for post-operative use, topical NSAIDs are also routinely used pre-operatively to better reduce inflammation as well as to prevent miosis during operative procedures, and this practice is supported by results from clinical studies.^{34,35} Furthermore, although studies have found no significant differences between the efficacy of NSAIDs and corticosteroids, NSAIDs do appear to be more effective at rebuilding the BAB.^{10,36} Diclofenac, ketorolac and nepafenac are indicated for the reduction of ocular pain following corneal refractive surgery and some physicians also use topically applied NSAIDs to reduce pain after corneal abrasions.

The efficacy and safety of topical ophthalmic NSAIDs in the control of ocular inflammation and pain are well known;^{14,33,38–44} however, two common local and transient adverse events following NSAID application are burning and stinging.^{12,14} For example, ketorolac and diclofenac cause transient burning and stinging in 40 and 15% of patients, respectively.⁴⁵ These adverse events may affect the patient's ocular comfort, compliance and persistence to treatment.

Although CMO is not a disease in itself, it is the most common cause of decline in vision following cataract surgery and is caused by

the accumulation of fluid in the central retina. Approximately 20–30% of patients who undergo uncomplicated surgery develop angiographically proven CMO.⁴⁶ However, a clinically significant decrease in visual acuity is seen only in approximately 1–2% of patients.⁴⁷ If cataract extraction is complicated by posterior capsule rupture and vitreous loss, severe iris trauma or vitreous traction at the wound, there is a significantly higher incidence of up to 20% of clinically apparent CMO.⁴⁸ Inflammation due to trauma from surgery and the destruction of the BAB are thought to be part of the pathogenesis of CMO, but the exact causes are unknown.⁴⁹ Symptoms include blurry or reduced central vision and painless retinal inflammation or swelling, but CMO is predominantly asymptomatic. Permanent loss of vision from CME is rare.³³ However, in high-risk patients routine measure of CMO by optical coherence tomography should be conducted following cataract surgery as part of the follow-up schedule.⁵⁰ There is no approved therapy for prevention of CMO despite the evidence supporting the potential benefits of NSAIDs for the treatment of this condition.^{51,52} Studies to date have investigated the use of NSAIDs in conjunction with corticosteroids. Since the two have somewhat different mechanisms of action, their combination may offer synergistic activity to minimise post-operative ocular inflammation.^{41,53}

PGs are first-line therapy for the treatment of glaucoma and ocular hypertension and are used by a significant number of patients admitted for cataract surgery. However, PGs are released naturally from the iris and ciliary body during cataract surgery and migrate to the retina. Additional PG therapy is thought to contribute to the onset of post-surgery CMO. Therefore, it has been advocated to discontinue the use of PGs up to two weeks before surgery and replace with an alternative form of therapy.⁵⁰

Future Treatment Options – Can Less Frequent Dosing Improve Compliance with Ophthalmic Therapy?

The currently available topical ophthalmic NSAIDs have frequent dosing schedules (three- or four-times daily). There is evidence from several clinical studies, mainly in glaucoma patients, suggesting that improvements in patient compliance can be associated with less frequent dosing.^{54–59} Therefore, it may be predicted that an NSAID with a less frequent dosing schedule could potentially offer improved patient compliance and persistence to treatment. It has also been suggested that reduced dosing schedules may reduce corneal epithelial toxicity since the patient's exposure to the drug and to potentially toxic preservatives would be reduced.⁶⁰

The twice-daily topical ophthalmic NSAID, bromfenac, is approved in Japan and the US (in 2000 and 2005, respectively), for the treatment of post-operative inflammation and/or ocular pain after cataract surgery, and is currently undergoing European regulatory review. It may, therefore, become another treatment option in this market.

The Pharmacokinetic Profile of the Bromfenac Ophthalmic Solution

Bromfenac is a derivative of amfenac that includes an additional bromonium ion. This enhances the lipophilicity of bromfenac, which in turn may facilitate penetration of the compound into all ocular tissues and thereby enhance the drug's potency.^{12,14,61–64} This pharmacokinetic profile will likely be the major contributing factor to the molecules' deep tissue penetration, early and sustained drug levels demonstrated in

ocular tissues,⁶¹ the lower dosing frequency with bromfenac and high anti-inflammatory potency.

In vitro studies have shown that bromfenac consistently provides highly potent inhibition of COX-2 relative to other NSAIDs. Invariably, these studies have shown that the inhibition of prostaglandin synthesis with bromfenac, and hence *in vitro* potency, as measured by its high COX-1/COX-2 IC50 ratio, was preferentially through COX-2 inhibition, resulting in greater inhibitory effect than most other available NSAIDs.^{62,63,65–67,68} As these are *in vitro* studies that had different designs and used different laboratory technologies, it is difficult to translate these results into clinical practice. Penetration of ocular tissues is also thought to be an important determinant of the efficacy of ophthalmic NSAIDs. Studies on bromfenac have demonstrated that the drug penetrates rapidly and deeply throughout the ocular tissues,^{61,68,65} which makes twice-daily dosing sufficient.

Clinical Efficacy and Safety of the Bromfenac Ophthalmic Solution

One of the first *in vivo* studies demonstrating the efficacy of topical bromfenac on ocular inflammation, performed in Japan, showed that bromfenac was almost 11 times more potent than pranoprofen at preventing the production of prostaglandins from rabbit iris ciliary body.⁶⁴ More recently, the pooled results of two large double-blinded, phase III trials have been reported.²⁶ In those trials, post-cataract surgery subjects who had moderate to severe signs of anterior segment inflammation at baseline were randomly assigned to either bromfenac or placebo (both twice-daily [BID]) for 14 days. Unusually for this type of trial, patients were not subjected to pre-dosing of bromfenac or concomitant steroid use before randomisation and treatment was initiated 24-hours post-operation.

The main outcome measure was cleared ocular inflammation with a summed ocular inflammation score (SOIS) of 0 (cells ≤ 5 and absence of flare examined at the slit lamp after 14 days of treatment). Secondary measures included time to resolution of ocular inflammation and time to resolution of ocular pain. Safety was also evaluated in this study. The anti-inflammatory effects of bromfenac at each post-treatment visit were statistically significant ($p < 0.0001$) compared with placebo, even as early as three days post-initiation of treatment ($p = 0.0012$, see *Table 2*). In terms of ocular comfort, ocular events (including burning, stinging and eye irritation) were only mild and occurred less frequently in bromfenac- versus placebo-treated subjects. Importantly, the incidence of burning and stinging with bromfenac is one of the lowest versus the other available topical ophthalmic NSAIDs.^{67–70} Transient burning and stinging have been reported in 1.4%⁶⁷ of patients applying bromfenac sodium 0.09% compared with 40%⁷⁰ applying ketorolac tromethamine and 15%⁶⁸ applying diclofenac sodium 0.1%.

Although there are currently no large head-to-head trials comparing bromfenac with other currently available topical ophthalmic NSAIDs, based on smaller studies, bromfenac seems to be at least as efficacious as the other topical ophthalmic NSAIDs at a lower dosing frequency. Previously published studies with other ophthalmic NSAIDs including diclofenac and ketorolac did not demonstrate clearance of ocular inflammation but only demonstrated a decrease in the level of cells and flare.^{71,72} A separate but similar trial of ketorolac versus a placebo showed that treatment with ketorolac did not completely clear inflammation in a statistically significant

proportion of subjects until day 14.⁷³ In another study, a statistically significant change from baseline in anterior chamber cell score was not observed until day 6, as reported for ketorolac.⁷⁴ In a prospective, randomised study, bromfenac was as effective as betamethasone in the treatment of post-operative inflammation after cataract surgery.⁷⁵

In the pivotal clinical studies bromfenac has shown some potential to reduce the risk of CME, with a reported 30% lower incidence of CME (1.4% in the active group versus 4.7% in the vehicle alone group).²⁶ Less retinal thickening has also been shown in another study at four and six weeks after cataract surgery in patients with non-proliferative diabetic retinopathy.⁷⁶

Since approval in Japan in 2000 and in the US in 2005, it has been possible to collect spontaneous adverse events reports for more than 20 million patients treated with bromfenac up to January 2010, with only a few cases of corneal epithelial complications.⁷⁷ Bromfenac has a well-established global efficacy and safety profile with no reported serious systemic adverse events.^{65,78}

Future Directions – Towards a New Standard in Post-operative Inflammation Efficacy?

The future direction in post-operative inflammation still has many avenues to improve. One key question of treatment that needs to be addressed is whether monotherapy with an NSAID is enough for the treatment of post-operative ocular inflammation, or should a corticosteroid be administered concurrently?

Experts believe that due to the disruption of the blood–ocular barrier during surgery, patients are more susceptible to inflammation in the early post-operative period. There is some suggestion that aggressive intervention with steroids in the early post-operative period would prevent the onset of inflammation. However, as prolonged use of steroids may cause IOP spikes, they should be replaced with NSAIDs, which are potent inhibitors of COX, but may be better tolerated.⁵⁰


A once-daily version of bromfenac is being developed in the US for the treatment of ocular inflammation and pain. Positive preliminary phase III results were announced in August 2009. Statistically significant results were obtained for the primary end-point of absence of ocular inflammation 15 days following cataract surgery. Statistically significant results were also obtained for the secondary end-point of elimination of ocular pain one day post-surgery. No serious ocular or systemic adverse events were reported. A supplemental US New Drug Application (NDA) was filed in December 2009.⁷⁹

Conclusions

Topical ophthalmic NSAIDs offer better, or at least similar, efficacy to the topical corticosteroids in the treatment of post-operative ocular inflammation and/or pain following cataract surgery, with fewer side-effects.

In clinical practice, an optimal ophthalmic NSAID therapy will have highly effective anti-inflammatory activity, a rapid onset of action that produces sustained relief of inflammation, a formulation that is comfortable and well tolerated, and a convenient dosing regimen. Based upon its features, bromfenac seems to satisfy these parameters.

Twice-daily dosing with bromfenac ophthalmic solution is effective for treatment of ocular inflammation after cataract surgery without the need for pre-treatment. Moreover, twice-daily bromfenac demonstrates an early and sustained level of clinical action with little burning and stinging and minimal adverse events. The twice-daily dosing schedule makes bromfenac a more convenient treatment regimen for inflammation compared with other NSAIDs, potentially enhancing patient compliance and adherence to the recommended dosing schedule. Other factors such as less exposure to the preservative, benzalkonium chloride, in NSAID solutions due to less dosing frequency (twice daily) and no shaking required before administration make bromfenac an attractive option.²⁶ A once-daily version of bromfenac will, potentially, further enhance patient compliance and adherence. ■



Oliver Findl is Associate Professor of Ophthalmology and Director of Department of Ophthalmology in Hanusch Hospital in Vienna, Austria, and is a Consultant Ophthalmic Surgeon at Moorfields Eye Hospital in London, UK. He initiated and heads the Vienna Institute of Research in Ophthalmic Surgery. Dr Findl was a research fellow at Children's Hospital, Harvard University, Boston and completed his training at the Medical University in Vienna. His research

interests are in the field of optical biometry, PCO and assessment of visual quality after surgery. He has published over 160 peer-reviewed articles in international journals. He is section editor for Reviews & Updates of the *Journal of Cataract and Refractive Surgery* and editorial board member of *Eurotimes*. He has been a member of the Board of the European Society of Cataract and Refractive Surgeons for five years.

- El-Harazi SM, Feldman RM, Control of intra-ocular inflammation associated with cataract surgery, *Curr Opin Ophthalmol*, 2001;12:4-8.
- Schalnus R, Topical nonsteroidal anti-inflammatory therapy in ophthalmology, *Ophthalmologica*, 2003;217:89-98.
- Simone JN, Whitacre MM, Effects of anti-inflammatory drugs following cataract extraction, *Curr Opin Ophthalmol*, 2001;12:63-7.
- Bhargava A, Jackson WB, El-Defrawy SR, Ocular allergic disease, *Drugs Today (Barc)*, 1998;34:957-71.
- Ferguson VM, Spalton DJ, Recovery of the blood-aqueous barrier after cataract surgery, *Br J Ophthalmol*, 1991;75:106-10.
- Havener WH, Corticosteroids therapy. In: *Ocular Pharmacology*, 5th edn, St Louis, MO: CV Mosby, 1983; 433-500.
- Schacke H, Docke WD, Asadullah K, Mechanisms involved in the side effects of glucocorticoids, *Pharmacol Ther*, 2002;96:23-43.
- McGhee CN, Dean S, Danesh-Meyer H, Locally administered ocular corticosteroids: benefits and risks, *Drug Saf*, 2002;25:33-55.
- Flach AJ, Topical nonsteroidal anti-inflammatory drugs in ophthalmology, *Int Ophthalmol Clin*, 2002;42:1-11.
- Roberts CW, Brennan KM, A comparison of topical diclofenac with prednisolone for postcataract inflammation, *Arch Ophthalmol*, 1995;113:725-7.
- El-Harazi SM, Ruiz RS, Feldman RM, et al., A randomized double-masked trial comparing ketorolac tromethamine 0.5%, diclofenac sodium 0.1%, and prednisolone acetate 1% in reducing post-phacoemulsification flare and cells, *Ophthalmic Surg Lasers*, 1998;29:539-44.
- Ahuja M, Dhake AS, Sharma SK, et al., Topical ocular delivery of NSAIDs, *AAPS J*, 2008;10:229-41.
- Gaynes BI, Fiscella R, Topical nonsteroidal anti-inflammatory drugs for ophthalmic use: a safety review, *Drug Saf*, 2002;25:233-50.
- Kim SJ, Flach AJ, Jampol LM, Nonsteroidal anti-inflammatory drugs in ophthalmology, *Surv Ophthalmol*, 2010;55:108-33.
- Kraff MC, Sanders DR, McGuigan L, et al., Inhibition of blood-aqueous humor barrier breakdown with diclofenac. A fluorophotometric study, *Arch Ophthalmol*, 1990;108:380-83.
- Simone JN, Pendelton RA, Jenkins JE, Comparison of the efficacy and safety of ketorolac tromethamine 0.5% and prednisolone acetate 1% after cataract surgery, *J Cataract Refract Surg*, 1999;25:699-704.
- Abelson MB, Schaefer K, Conjunctivitis of allergic origin: immunologic mechanisms and current approaches to therapy, *Surv Ophthalmol*, 1993;(Suppl 38):115-32.
- Armary MF, Effect of Corticosteroids on Intraocular Pressure and Fluid Dynamics. I. The Effect of Dexamethasone in the Normal Eye, *Arch Ophthalmol*, 1963;70:482-91.
- Friedlaender MH, Corticosteroid therapy of ocular inflammation, *Int Ophthalmol Clin*, 1983;23:175-82.
- Gieser DK, Hodapp E, Goldberg I, et al., Flurbiprofen and intraocular pressure, *Ann Ophthalmol*, 1981;13:831-3.
- Syed NA, Hyndiuk RA, Infectious conjunctivitis, *Infect Dis Clin North Am*, 1992;6:789-805.
- Waterbury L, Kunysz EA, Beuerman R, Effects of steroidal and non-steroidal anti-inflammatory agents on corneal wound healing, *J Ocul Pharmacol*, 1987;3:43-54.
- Chin MS, Nagineni CN, Hooper LC, et al., Cyclooxygenase-2 gene expression and regulation in human retinal pigment epithelial cells, *Invest Ophthalmol Vis Sci*, 2001;42:2338-46.
- Ku EC, Signor C, Eakins E, Anti-inflammatory agents and inhibition of ocular prostaglandin synthetase, *Adv Prostaglandin Thromboxane Res*, 1976;2:819-23.
- Miyake K, Mibu H, Horiguchi M, et al., Inflammatory mediators in postoperative aphakic and pseudophakic baboon eyes, *Arch Ophthalmol*, 1990;108:1764-7.
- Donnenfeld ED, Holland EJ, Stewart RH, et al., Bromfenac ophthalmic solution 0.09% (Xibrom) for postoperative ocular pain and inflammation, *Ophthalmology*, 2007;114:1653-62.
- Findl O, Amon M, Kruger A, et al., Effect of cooled intraocular irrigating solution on the blood-aqueous barrier after cataract surgery, *J Cataract Refract Surg*, 1999;25:566-8.
- Schuaersberger J, Kruger A, Mullner-Eidenbock A, et al., Long-term disorders of the blood-aqueous barrier after small-incision cataract surgery, *Eye (Lond)*, 2000;14(Pt 1):61-3.
- Peternel V, Findl O, Kruger A, et al., Effect of tropicamide on aqueous flare before and after cataract surgery, *J Cataract Refract Surg*, 2000;26:382-5.
- Oshika T, Kato S, Changes in aqueous flare and cells after mydriasis, *Jpn J Ophthalmol*, 1989;33:271-8.
- Shah SM, Spalton DJ, Smith SE, Measurement of aqueous cells and flare in normal eyes, *Br J Ophthalmol*, 1991;75:348-52.
- Findl O, Amon M, Peternel V, et al., Early objective assessment of intraocular inflammation after phacoemulsification cataract surgery, *J Cataract Refract Surg*, 2003;29:2143-7.
- O'Brien TP, Emerging guidelines for use of NSAID therapy to optimize cataract surgery patient care, *Curr Med Res Opin*, 2005;21:1131-7.
- Roberts CW, Pretreatment with topical diclofenac sodium to decrease postoperative inflammation, *Ophthalmology*, 1996;103:636-9.
- Solomon KD, Turkalj JW, Whiteside SB, et al., Topical 0.5% ketorolac vs 0.03% flurbiprofen for inhibition of miosis during cataract surgery, *Arch Ophthalmol*, 1997;115:1119-22.
- Flach AJ, Cyclo-oxygenase inhibitors in ophthalmology, *Surv Ophthalmol*, 1992;36:259-84.
- Kapin MA, Yanni JM, Brady MT, et al., Inflammation-mediated retinal edema in the rabbit is inhibited by topical nepafenac, *Inflammation*, 2003;27:281-91.
- Snyder RW, Siekert RW, Schwiogerling J, et al., Acular as a single agent for use as an antimiotic and anti-inflammatory in cataract surgery, *J Cataract Refract Surg*, 2000;26:1225-7.
- Nichols J, Snyder RW, Topical nonsteroidal anti-inflammatory agents in ophthalmology, *Curr Opin Ophthalmol*, 1998;9:40-44.
- McColgin AZ, Heier JS, Control of intraocular inflammation associated with cataract surgery, *Curr Opin Ophthalmol*, 2000;11:3-6.
- Heier JS, Topping TM, Baumann W, et al., Ketorolac versus prednisolone versus combination therapy in the treatment of acute pseudophakic cystoid macular edema, *Ophthalmology*, 2000;107:2034-8;discussion 9.
- Seitz B, Sorken K, LaBree LD, et al., Corneal sensitivity and burning sensation. Comparing topical ketorolac and diclofenac, *Arch Ophthalmol*, 1996;114:921-4.
- Nardi M, Lobo C, Bereczki A, et al., Analgesic and anti-inflammatory effectiveness of nepafenac 0.1% for cataract surgery, *Clin Ophthalmol*, 2007;1:527-33.
- Lane SS, Modi SS, Lehmann RP, et al., Nepafenac ophthalmic suspension 0.1% for the prevention and treatment of ocular inflammation associated with cataract surgery, *J Cataract Refract Surg*, 2007;33:53-8.
- MedicineNet, Eye Allergy, Web Page, 2010, http://www.medicinenet.com/eye_allergy/page4.htm. (accessed 27 August 2010).
- Peterson M, Yoshizumi MO, Hepler R, et al., Topical indomethacin in the treatment of chronic cystoid macular edema, *Graefes Arch Clin Exp Ophthalmol*, 1992;30:401-5.
- Bergman M, Laatikainen L, Cystoid macular oedema after complicated cataract surgery and implantation of an anterior chamber lens, *Acta Ophthalmol (Copenh)*, 1994;72:178-80.
- Rotsos TG, Moschos MM, Cystoid macular edema, *Clin Ophthalmol*, 2008;2:919-30.
- Colin J, The role of NSAIDs in the management of postoperative ophthalmic inflammation, *Drugs*, 2007;67:1291-308.
- Guidelines for managing post-cataract surgery inflammation. Can we reach a consensus?, *Ophthalmol Times Europe*, 2008.
- Rossetti L, Chaudhuri J, Dickersin K, Medical prophylaxis and treatment of cystoid macular edema after cataract surgery. The results of a meta-analysis, *Ophthalmology*, 1998;105:397-405.
- Flach AJ, The incidence, pathogenesis and treatment of cystoid macular edema following cataract surgery, *Trans Am Ophthalmol Soc*, 1998;96:557-634.
- Flach AJ, Discussion by Allan J Flach, MD, *Ophthalmology*, 2000;107:2039.
- Taylor SA, Galbraith SM, Mills RP, Causes of non-compliance with drug regimens in glaucoma patients: a qualitative study, *J Ocul Pharmacol Ther*, 2002;18:401-9.
- Patel SC, Spaeth GL, Compliance in patients prescribed eyedrops for glaucoma, *Ophthalmic Surg*, 1995;26:233-6.
- Schenker H, Maloney S, Liss C, et al., Patient preference, efficacy, and compliance with timolol maleate ophthalmic gel-forming solution versus timolol maleate ophthalmic solution in patients with ocular hypertension or open-angle glaucoma, *Clin Ther*, 1999;21:138-47.
- Eisen SA, Miller DK, Woodward RS, et al., The effect of

- prescribed daily dose frequency on patient medication compliance, *Arch Intern Med*, 1990;150:1881–4.
58. Ikeda H, Sato M, Tsukamoto H, et al., Evaluation and multivariate statistical analysis of factors influencing patient adherence to ophthalmic solutions, *Yakugaku Zasshi*, 2001;121:799–806.
 59. Stewart WC, Konstas AG, Pfeiffer N, Patient and ophthalmologist attitudes concerning compliance and dosing in glaucoma treatment, *J Ocul Pharmacol Ther*, 2004;20:461–9.
 60. Cha SH, Lee JS, Oum BS, et al., Corneal epithelial cellular dysfunction from benzalkonium chloride (BAC) in vitro, *Clin Experiment Ophthalmol*, 2004;32:180–4.
 61. Baklayan GA, Patterson HM, Song CK, et al., 24-hour evaluation of the ocular distribution of (14)C-labeled bromfenac following topical instillation into the eyes of New Zealand White rabbits, *J Ocul Pharmacol Ther*, 2008;24:392–8.
 62. Cho H, Wolf KJ, Wolf EJ, Management of ocular inflammation and pain following cataract surgery: focus on bromfenac ophthalmic solution, *Clin Ophthalmol*, 2009;3:199–210.
 63. Sancilio LF, Nolan JC, Wagner LE, et al., The analgesic and anti-inflammatory activity and pharmacologic properties of bromfenac, *Arzneimittelforschung*, 1987;37:513–19.
 64. Walsh DA, Moran HW, Shamblee DA, et al., Antiinflammatory agents. 3. Synthesis and pharmacological evaluation of 2-amino-3-benzoylphenylacetic acid and analogues, *J Med Chem*, 1984;27:1379–88.
 65. Donnenfeld ED, Donnenfeld A, Global experience with Xibrom (bromfenac ophthalmic solution) 0.09%: the first twice-daily ophthalmic nonsteroidal anti-inflammatory drug, *Int Ophthalmol Clin*, 2006;46:21–40.
 66. Ogawa T, Sakaue T, Terai T, et al., Effects of bromfenac sodium, non-steroidal anti-inflammatory drug, on acute ocular inflammation, *Nippon Ganka Gakkai Zasshi*, 1995;99:406–11.
 67. Xibrom [package insert]. Irvine, CA: ISTA Pharmaceuticals, Inc.
 68. Acular [package insert]. Irvine, CA: Allergan, Inc.
 69. Nevanac [package insert]. Fort Worth, TX: Alcon Laboratories, Inc.
 70. Voltaren [package insert]. East Hanover, NJ: Novartis Pharmaceuticals Corporation.
 71. Kraff MC, Martin RG, Neumann AC, et al., Efficacy of diclofenac sodium ophthalmic solution versus placebo in reducing inflammation following cataract extraction and posterior chamber lens implantation, *J Cataract Refract Surg*, 1994;20:138–44.
 72. Flach AJ, Dolan BJ, Donahue ME, et al., Comparative effects of ketorolac 0.5% or diclofenac 0.1% ophthalmic solutions on inflammation after cataract surgery, *Ophthalmology*, 1998;105:1775–9.
 73. Heier J, Cheetham JK, Degryse R, et al., Ketorolac tromethamine 0.5% ophthalmic solution in the treatment of moderate to severe ocular inflammation after cataract surgery: a randomized, vehicle-controlled clinical trial, *Am J Ophthalmol*, 1999;127:253–9.
 74. Solomon KD, Cheetham JK, DeGryse R, et al., Topical ketorolac tromethamine 0.5% ophthalmic solution in ocular inflammation after cataract surgery, *Ophthalmology*, 2001;108:331–7.
 75. Miyanaga M, Miyai T, Nejima R, et al., Effect of bromfenac ophthalmic solution on ocular inflammation following cataract surgery, *Acta Ophthalmol*, 2009;87:300–305.
 76. Endo N, Kato S, Haruyama K, et al., Efficacy of bromfenac sodium ophthalmic solution in preventing cystoid macular oedema after cataract surgery in patients with diabetes, *Acta Ophthalmol*, 2009; [Epub ahead of print].
 77. Data on file, ISTA Pharmaceuticals, Inc.
 78. Miyake-Kashima M, Takano Y, Tanaka M, et al., Comparison of 0.1% bromfenac sodium and 0.1% pemirolast potassium for the treatment of allergic conjunctivitis, *Jpn J Ophthalmol*, 2004;48:587–90.
 79. ISTA, XiDay™, Web Page, 2010, <http://www.istavision.com/research-development/xiday.html> (accessed 27 August 2010).