

The Blood–Retinal Barrier in Retinal Disease

José Cunha-Vaz

President, Association for Innovation and Biomedical Research on Light and Image

Abstract

The blood–ocular barrier system is formed by two main barriers: the blood–aqueous barrier and the blood–retinal barrier (BRB). The BRB is particularly tight and restrictive and is a physiological barrier that regulates ion, protein and water flux into and out of the retina. The BRB consists of inner and outer components, the inner BRB being formed of tight junctions between retinal capillary endothelial cells and the outer BRB of tight junctions between retinal pigment epithelial cells. The BRB is essential to maintaining the eye as a privileged site and is essential for normal visual function. Alterations of the BRB play a crucial role in the development of retinal diseases. The two most frequent and relevant retinal diseases, diabetic retinopathy and age-related macular degeneration (AMD), are directly associated with alterations of the BRB. Diabetic retinopathy is initiated by an alteration of the inner BRB and neovascular AMD is a result of an alteration of the outer BRB. Treatment of retinal diseases must also deal with the BRB either by using its specific transport mechanisms or by circumventing it through intravitreal injections.

Keywords

Blood–retinal barrier, blood–ocular barriers, retinal vessels, retinal vascular endothelium, retinal pigment epithelium, blood–aqueous barrier, macular oedema, vitreous fluorometry, retinal leakage analyser, retinal tight junctions, diabetic retinopathy, retinal drug delivery

Disclosure: The author has no conflicts of interest to declare.

Received: 29 July 2009 **Accepted:** 27 October 2009 *DOI:* 10.17925/EOR.2009.03.02.105

Correspondence: José Cunha-Vaz, AIBILI, Azinhaga Santa Comba, Celas, 3000-548 Coimbra, Portugal. E: cunhavaz@aibili.pt

The entire eye must function as the organ for vision and is organised with two major goals: normal function of the visual cell and the need to maintain ideal optical conditions for the light to access the visual cells, located in the back of the eye. The blood–ocular barriers play a fundamental role in the preservation and maintenance of the appropriate environment for optimal visual cell function.¹ The blood–ocular barriers include two main barrier systems – the blood–aqueous barrier and the blood–retinal barrier (BRB) – which are fundamental to keeping the eye as a privileged site in the body by regulating the contents of its inner fluids and preserving the internal ocular tissues from the variations that occur constantly in the whole circulation. The BRB, similar to the blood–brain barrier (BBB), is particularly tight and restrictive and is a physiological barrier that regulates ion, protein and water flux into and out of the retina.²

The blood–ocular barriers must not only provide a suitable, highly regulated chemical environment for the avascular transparent tissues of the eye, but also serve as a drainage route for the waste products of the metabolic activity of the ocular tissues. It is also important to realise that once inside these barriers there are no major diffusional barriers between the extracellular fluid of the retina and adjacent vitreous humour; nor does the vitreous body itself significantly hinder the diffusional exchanges between the posterior chamber and the retinal extracellular fluid. This means that the functions of both barriers – the blood–aqueous barrier and the BRB – influence each other and must work in equilibrium.³

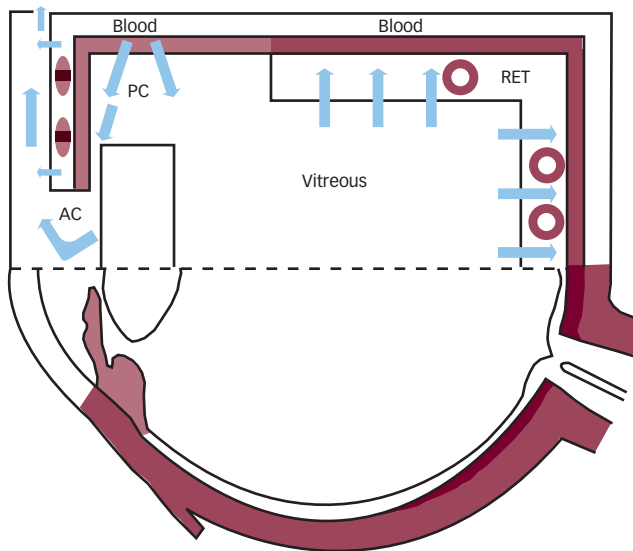
Blood–Retinal Barrier

The BRB consists of inner and outer components (inner BRB [iBRB] and outer BRB [oBRB]) and plays a fundamental role in the microenvironment of the retina and retinal neurons. It regulates fluids and molecular movement between the ocular vascular beds and retinal tissues and prevents leakage into the retina of macromolecules and other potentially harmful agents (see *Figures 1* and *2*).

The iBRB is established by the tight junctions (zonulae occludentes) between neighbouring retinal endothelial cells.^{4,5} The retinal endothelial layer functions as an ‘epithelium’ and in this way is directly associated with its differentiation and with the polarisation of BRB function. This continuous endothelial cell layer, which forms the main structure of the iBRB, rests on a basal lamina that is covered by the processes of astrocytes and Müller cells. Pericytes are also present, encased in the basal lamina, in close contact with the endothelial cells, but they do not form a continuous layer and therefore do not contribute to the diffusional barrier. Astrocytes, Müller cells and pericytes are considered to influence the activity of retinal endothelial cells and of the iBRB by transmitting regulatory signals to endothelial cells indicating changes in the microenvironment of the retinal neuronal circuitry.

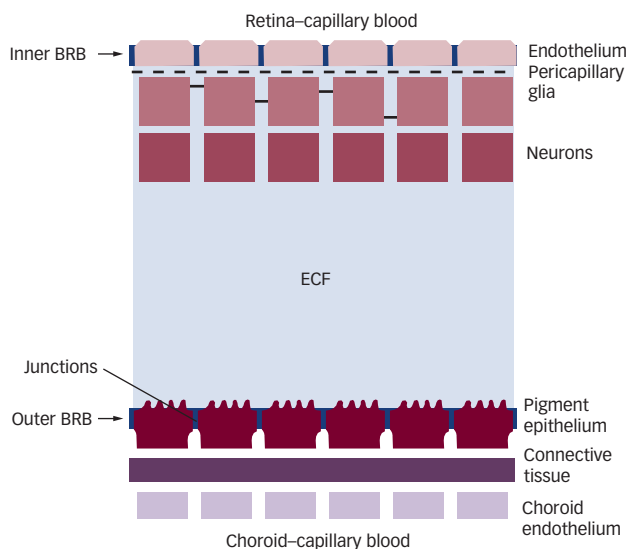
The oBRB is established by the tight junctions (zonulae occludentes) between neighbouring retinal pigment epithelial (RPE) cells.^{4,7} The RPE is composed of a single layer of retinal pigment epithelial cells that are joined laterally towards their apices by tight junctions between adjacent lateral cell walls. The RPE, resting on the underlying Bruch’s

Figure 1: Schematic Drawing of the Blood–Ocular Barriers and Main Fluid Movements



AC = anterior chamber; PC = posterior chamber; RET = retina.

Figure 2: Schematic Representation of the Inner and Outer Blood–Retinal Barriers and Their Relative Locations



ECF = extracellular fluid.

membrane, separates the neural retina from the fenestrated choriocapillaries and plays a fundamental role in regulating access of nutrients from the blood to the photoreceptors, as well as eliminating waste products and maintaining retinal adhesion. The metabolic relationship of the RPE apical villi and the photoreceptors is considered to be critical for the maintenance of visual function.

In both the iBRB and the oBRB, the tight cell junctions restrict paracellular movement of fluids and molecules between blood and retina, and the endothelial cells and RPE cells actively regulate inward and outward movement.⁸ As a result, the levels of amino acids and fatty acids in the blood plasma fluctuate over a wide range while their concentrations in the retina remain relatively stable.

A close spatial relationship exists between Müller cells and blood vessels in the retina, suggesting a critical role for these cells in the formation and maintenance of the BRB, regulating the function of barrier cells in the uptake of nutrients and in the disposal of metabolites under normal conditions. Barrier function is also impaired by matrix metalloproteinases (MMPs) from Müller cells, as these MMPs lead to proteolytic degradation of the tight-junction protein occludin.

The Blood–Retinal Barrier and Ocular Immune Privilege

The immune response has developed and evolved to protect the organism from invasion and damage by a wide range of pathogens. With time, the immune system has developed destructive responses that are specific for pathogens as well as tissues. However, such tissue injury may have a devastating effect on the function of an organ such as the eye, which needs to maintain optical stability.

The existence of ocular immune privilege is dependent on multiple factors such as immunomodulatory factors and ligands, regulation of the complement system within the eye, tolerance-promoting antigen-presenting cells (APCs), unconventional drainage pathways and, with particular relevance, the existence of the blood–ocular barriers.⁹

The blood–ocular barriers provide a relative sequestration of the anterior chamber, vitreous humour and neurosensory retina from the immune system and create the necessary environment for the existence of ocular immune privilege. The evolution of immune privilege as a protective mechanism for preserving the function of vital and delicate organs such as the eye has resulted in a complex system with multiple regulatory safeguards for the control of both innate and adaptive immunity. The consequences of inadvertent bystander tissue destruction by antigen-non-specific inflammation can be so catastrophic to the organ or host that a finely tuned regulatory system is needed to ensure the integrity of the ocular tissues and maintain optical relationships.

There are also several lines of evidence that point to immunosuppressive functions in BRB cells, RPE and retinal endothelial cells. These immunosuppressive effects are apparently due to the secretion of a variety of soluble factors, such as cytokines and growth factors.

Clinical Evaluation of the Blood–Retinal Barrier

Fluorescein angiography, an examination procedure performed routinely in the ophthalmologist’s office, permits a dynamic evaluation of local circulatory disturbances and identifies the sites of BRB breakdown. However, it is only semi-quantitative and its reproducibility depends on the variable quality of the angiograms.

Vitreous fluorometry was developed as a method capable of quantifying both inward and outward movements of fluorescein across the BRB system in the clinical setting.¹⁰ Protocols were devised and tested, and dedicated instrumentation developed.

With the development of vitreous fluorometry methodologies, a large number of clinical and experimental studies have clearly demonstrated the major role played by alterations of the BRB in posterior segment disease. In clinical situations, alterations of the BRB have been measured in pathologies of the RPE, age-related macular degeneration (AMD), macular oedema, hypertension and

diabetes. However, the clinical use of this technique has declined because it offers only an overall measurement of the posterior pole and because at the time of its development there were no drugs available for stabilising the BRB. Nowadays, vitreous fluorometry is mostly used in experimental research and in drug development.

More recently, retinal leakage mapping has been introduced to identify the sites of BRB breakdown.¹¹ Further developments of this methodology based on confocal scanning laser ophthalmology (SLO), such as the retinal leakage analyser (see *Figure 3*), along with improved optical coherence tomography imaging are expected to contribute to earlier diagnosis of BRB alterations in retinal disease, as well as improved testing of the effect of new drugs that are now becoming available for the treatment of retinal disease.

Blood–Retinal Barrier and Macular Oedema

Macular oedema is the result of an accumulation of fluid in the retinal layers around the fovea, contributing to vision loss by altering the functional cell relationship in the retina and promoting an inflammatory reparative response. Macular oedema is a non-specific sign of ocular disease, not a specific entity. It should be viewed as a special and clinically relevant type of macular response to an altered retinal environment, in most cases associated with an alteration of the BRB. It occurs in a wide variety of ocular situations, such as uveitis, trauma, intraocular surgery, vascular retinopathies, hereditary dystrophies, diabetes, AMD degeneration, etc.

The extracellular accumulation of fluid is directly associated with an alteration of the BRB. In this situation the protective effect of the BRB is lost and Starling’s law applies.¹² When there is breakdown of the BRB, any changes in the equilibrium between hydrostatic and oncotic pressure gradients across the BRB contribute to further water movements and progression of the macular oedema.

It is also relevant to keep in mind that the BRB cells, retinal endothelial cells and RPE cells are both the targets and producers of ecosanoids, growth factors and cytokines. Breakdown of the BRB leading to situations of macular oedema may be mediated by locally released cytokines and induces an inflammatory reparative response creating the conditions for further release of cytokines, growth factors, etc.

Blood–Retinal Barrier and Retinal Diseases

An alteration of the iBRB resulting from endothelial dysfunction is one of the initial alterations in diabetic retinal disease. It is this alteration of the iBRB that leads to diabetic macular oedema, the most frequent cause of vision loss due to diabetes, and that triggers most of the pathological changes that lead to retinopathy progression (see *Figure 4*).

In AMD, it is the integrity of the outer BRB that keeps the choroidal vascular response from invading the retina and changing dry AMD into wet AMD, which results in rapid vision loss (see *Figure 5*).

Breakdown of the BRB appears to be the best predictor of conversion to wet AMD. Other situations that are associated with breakdown of the BRB are retinal detachments and inflammatory diseases. The response in retinal disease is fundamentally a situation of massive breakdown of the BRB resulting from an abnormal BRB.

Figure 3: Sites of Fluorescein Leakage into the Vitreous Identified by the Retinal Leakage Analyser in an Eye with Non-proliferative Retinopathy in a Patient with Type 2 Diabetes

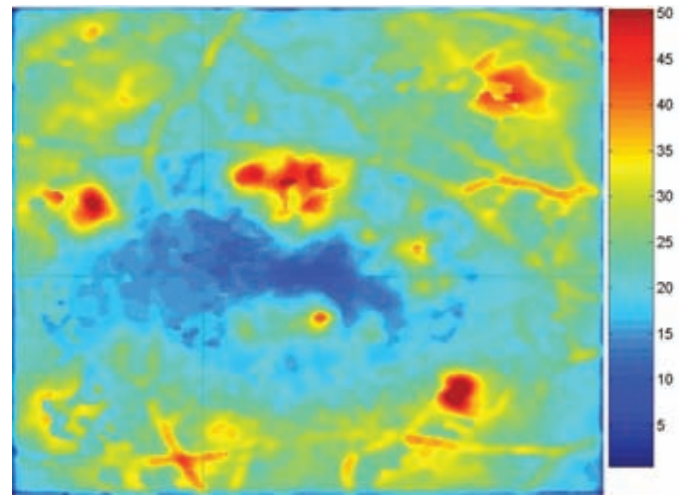


Figure 4: Role of Leakage (Breakdown of Blood–Retinal Barrier) in Diabetic Retinopathy

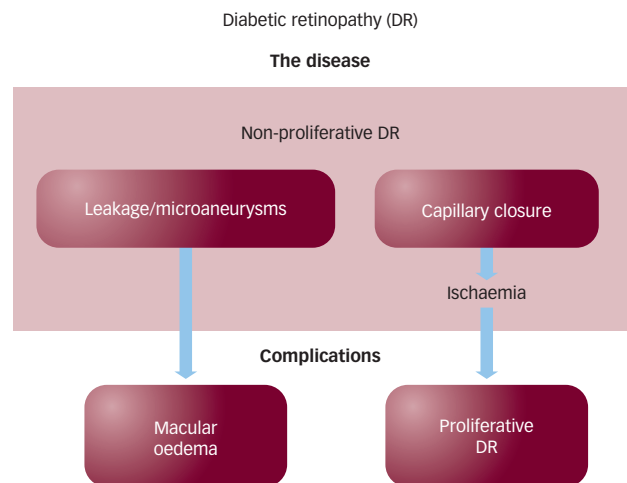
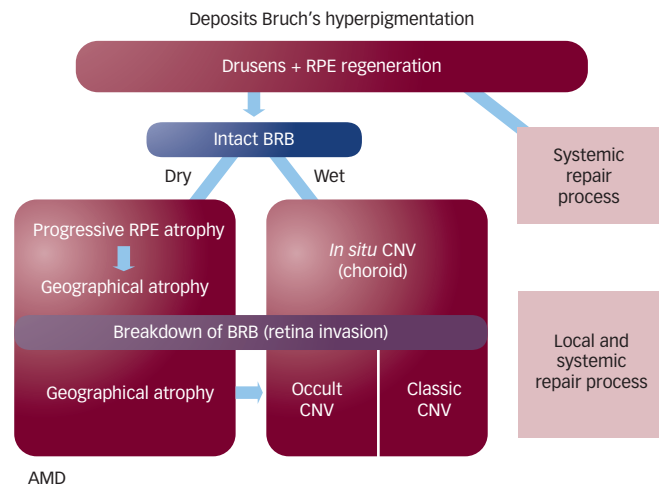


Figure 5: Role of Breakdown of the Blood–Retinal Barrier (Retinal Leakage) in Age-related Macular Degeneration



AMD = age-related macular degeneration; BRB = blood–retinal barrier; CNV = choroidal neovascularisation; RPE = retinal pigment epithelium.

Relevance of the Blood–Retinal Barrier to Treatment of Retinal Diseases

When administered systemically, drugs must pass the BRB in order to reach therapeutic levels in the retina. Drug entrance into the retina depends on a number of factors, including the plasma concentration profile of the drug, the volume of its distribution, plasma protein binding and the relative permeability of the BRB. To obtain therapeutic concentrations within the retina, new strategies must be considered such as delivery of nanoparticles, chemical modification of drugs to enhance BRB transport, coupling of drugs to vectors, etc.

From the viewpoint of drug delivery, designing drugs (including peptides) with greater lipophilicity to enhance BRB permeability seems to be an easy approach. However, such a strategy would not only increase permeation into tissues other than the retina, but also decrease bioavailability due to the hepatic first-pass metabolism in the case of oral administration. Accordingly, for the development of retina-specific drug delivery systems for neuroactive drugs, the most effective approach is to utilize the specific transport mechanisms active at the BRB. That would mean designing drugs that mimic the substrates to be taken by particular transporters or receptors existing in the BRB.

Eye drops are generally considered to be of limited benefit in the treatment of posterior segment diseases. Newer prodrug formulations that achieve high concentrations of the drug in the posterior segment may have a role in the future. Meanwhile, periocular injection is one modality that has offered mixed results.

Finally, recent years have seen a generalised and surprisingly safe utilisation of intravitreal injections, a form of administration that

circumvents the BRB. Steroids and a variety of anti-vascular endothelial growth factor (anti-VEGF) drugs have been administered through intravitreal injections to a large number of patients without significant side effects and demonstrating good acceptance by the patients. Intravitreal injections can achieve high drug concentrations in the vitreous humour and retina, preserving BRB integrity and its crucial protective function. At present, the major challenge appears to be the need to decrease the number of intravitreal injections, which, in the case of anti-VEGF treatments, are given every six weeks to maintain efficacy. The search for safe slow-delivery devices or implantable biomaterials is ongoing, but the invasive approach to retinal disease treatment appears to be an effective way of rapidly reaching therapeutic levels in the retina in the presence of a functioning BRB. ■



José Cunha-Vaz is a Professor of Ophthalmology and President of the Association for Innovation and Biomedical Research on Light and Image, a not-for-profit technology transfer organisation and clinical trial centre. Previously, he was a full-time Professor of Ophthalmology and Director of the Retina Service at the University of Illinois at Chicago. Professor Cunha-Vaz's work has included laboratory and clinical research in retina and intraocular fluids, with a special emphasis on

blood–retinal barriers and diabetic retinopathy. He initiated clinical vitreous fluorometry and multimodal macular mapping. Dr Cunha-Vaz is Co-ordinator of the European Network of Clinical Trial Centers of Ophthalmology (EVICTSE) and President of the European Society of Retina Specialists (Euretina). He has received many awards, such as the Diaz Caneja and Paul Henkind lectures, the Alcon Research Institute Award and the Helmholtz Gold Medal of the European Society of Ophthalmology (SOE). He has been distinguished by his country with the Orders of Merit in Public Instruction and Henry the Navigator. Dr Cunha-Vaz serves on the boards of many ophthalmic and diabetes journals and has published more than 44 book chapters and 417 peer-reviewed journal articles.

1. Cunha-Vaz JG, The blood–ocular barriers, *Surv Ophthalmol*, 1979;23:279–96.
2. Cunha-Vaz JG, Maurice DM, The active transport of fluorescein by retinal vessels and the retina, *J Physiol*, 1967;191:467–86.
3. Cunha-Vaz JG, Maurice DM, Fluorescein dynamics in the eye, *Doc Ophthalmol*, 1969;26:61–72.
4. Cunha-Vaz JG, Shakib M, Ashton N, Studies on the permeability of the blood–ocular barrier. I. On the existence, development and site of a blood–retinal barrier, *Br J Ophthalmol*, 1966;50:411–53.
5. Shakib M, Cunha-Vaz JG, Studies on the permeability of the blood–retinal barrier. IV. Junctional complexes of the retinal vessels and their role on their permeability, *Exp Eye Res*, 1966;5:229–34.
6. Peyman GA, Bok D, Peroxidase diffusion in the normal and laser-coagulated primate retina, *Invest Ophthalmol*, 1972;11:35–45.
7. Strauss O, The retinal pigment epithelium in visual function, *Physiol Rev*, 2005;85:845–81.
8. Philips BE, Antonetti DA, Blood–retinal barrier. In: Jousseaume AM, Gardner TW, Kirchhof B, Ryan SJ (eds), *Retinal Vascular Disease*, Berlin: Springer-Verlag, 2007;139–53.
9. Kaplan HJ, Niederkorn JY, Regional immunity and immune privilege. In: Niederkorn JY, Kaplan HG, *Immune Response and the Eye. Chemical Immunology Allergy*, Basel: Karger, 2007;92:11–26.
10. Cunha-Vaz JG, Faria de Abreu JR, Campos AJ, Figo G, Early breakdown of the blood–retinal barrier in diabetes, *Brit J Ophthalmol*, 1975;59:649–56.
11. Lobo C, Bernardes R, Cunha-Vaz JG, Mapping retinal fluorescein leakage with confocal scanning laser fluorometry of the human vitreous, *Arch Ophthalmol*, 1999;117:631–7.
12. Cunha-Vaz JG, Travassos A, Breakdown of the blood–retinal barriers and cystoid macular edema, *Surv Ophthalmol*, 1984;28:485–92.