

# The SOLX® Gold Shunt Device for Glaucoma

a report by

**Diamond Y Tam and Iqbal Ike K Ahmed**

University of Toronto

DOI: 10.17925/EOR.2009.02.01.39

Egress of aqueous humour out of the intraocular space occurs via two distinct pathways: conventional and uveoscleral. The conventional outflow pathway, which comprises the trabecular meshwork, Schlemm's canal and, ultimately, the intra- and episcleral venous plexus, has traditionally been thought to account for the majority of aqueous outflow. The uveoscleral outflow pathway, which comprises the interstitium of the ciliary body, the suprachoroidal space and, ultimately, egress through the scleral vasculature, has been reported to contribute anywhere from 20 to 54% of total aqueous humour egress in normal human eyes.<sup>1,2</sup> Elevated intraocular pressure (IOP) typically results from increased resistance or compromise in either or both outflow pathways. When IOP remains uncontrolled by maximally tolerated medical therapy combined with appropriately selected laser therapy in the setting of advancing glaucomatous optic neuropathy or visual field loss, surgical intervention becomes necessary. Traditionally, glaucoma surgery has consisted of subconjunctival filtration; however, there are significant limitations to such procedures. An alternative site for filtration is the suprachoroidal space, which is targeted by a new device, the gold shunt, and will be discussed here.

## Overview of Issues in Glaucoma Surgery

Glaucoma surgery has traditionally been dominated by subconjunctival filtration procedures such as trabeculectomy and seton device implantation, both of which lower IOP by providing a conduit for aqueous humour to travel from the anterior chamber to a subconjunctival reservoir, commonly known as a bleb. While in the majority of cases subconjunctival filtration has provided reliable IOP lowering, blebs have a sizeable complication profile, including a lifetime risk of blebitis and endophthalmitis, bleb leakage, fibrosis, encapsulation, overfiltration and hypotony, bleb dysesthesia, overhang onto the cornea, corneal dellen, malignant glaucoma and, in the case of tube shunt surgery, tube or plate exposure, corneal endothelial cell death, ptosis and diplopia. In addition, previous conjunctival surgery or conditions predisposing a patient to conjunctival scarring make subconjunctival filtration less desirable and more likely to fail. Because of the many issues with conventional subconjunctival glaucoma filtering surgery, there is no consistent solution for cases of refractory glaucoma for which existing techniques are not viable solutions. As a result, many recent efforts have been directed towards other methods by which IOP can be lowered surgically, including Schlemm's canal surgery and filtration into the suprachoroidal space.

In a monkey model measuring hydrostatic pressure in the suprachoroidal space via direct cannulation and silicone sponge implantation, Emi et al. showed a pressure differential from the anterior chamber into the suprachoroidal space that increased at higher IOP levels, driving uveoscleral outflow.<sup>3</sup> Uveoscleral outflow can be modulated both pharmacologically – by prostaglandin analogues such as latanoprost, travaprost and bimatoprost – and surgically – by procedures such as creation of a

cyclodialysis cleft, which involves separation of the ciliary body from the sclera via a trans-scleral approach. Such a procedure allows free communication from the anterior chamber into the suprachoroidal space, artificially augmenting uveoscleral outflow.<sup>4-8</sup> However, this procedure has several limitations, including the risk of intra- and post-operative haemorrhage due to the vascular nature of the uveal tissue, prolonged irreversible hypotony, late IOP spike due to unexpected cleft closure and scarring of the artificially created cleft. An *ab interno* approach was equally ineffective, with 75% of patients requiring further surgical intervention after the initial cyclodialysis creation at 60 days post-operatively.<sup>5</sup>

Other studies have investigated the placement of high-molecular-weight hyaluronic acid, teflon tube implants and other materials such as a hydroxyethyl methacrylate capillary strip and even a scleral strip into the cyclodialysis cleft to prevent closure and fibrosis of the cleft.<sup>9-12</sup> However, such implants have not been demonstrated to provide successful long-term IOP control in glaucomatous human eyes. While suprachoroidal implantation of seton devices has been reported, consistency and long-term success have yet to be demonstrated. Furthermore, implantation of devices of this size in the suprachoroidal space raises concerns about prolonged risk of suprachoroidal haemorrhage, choroidal detachment and atrophy and exudative retinal detachment.<sup>13-15</sup> Here we review a new suprachoroidal drainage device that does not have US Food and Drug Administration (FDA) approval: the gold shunt, currently in phase III of a randomised, controlled, multicentre comparative clinical trial.

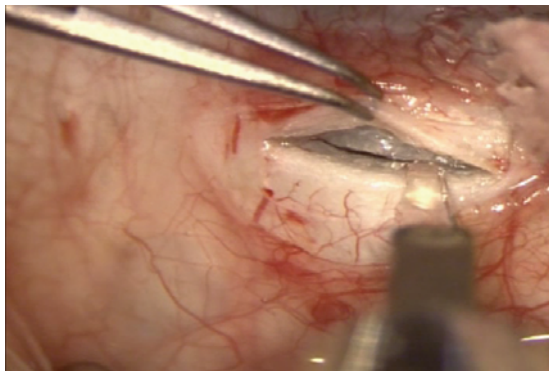
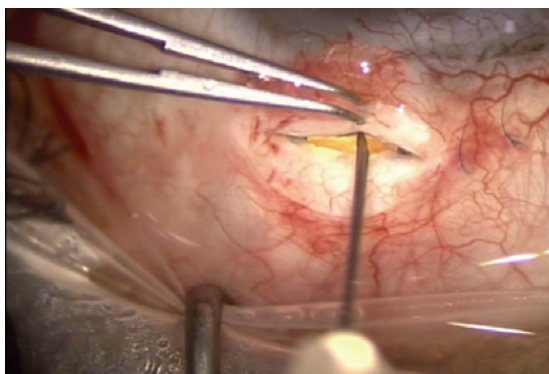
## The SOLX® Gold Shunt

The SOLX® gold shunt (SOLX Inc., Waltham, MA) is a 24-karat-gold implant 5.2mm long, 2.4mm wide anteriorly and 3.2mm wide posteriorly (see *Figure 1*). Elemental gold has been shown to have good biocompatibility and to be inert as a foreign body in the intraocular tissues.<sup>16,17</sup> Two models were studied: the GMS and GMS Plus. The GMS model is a 6.2mg, 60µ-thick structure concealing nine channels, each of which is 25µ wide and 44µ high, through which aqueous humour drains from the anterior aspect of the shunt (which is situated in the anterior chamber) to exit the posterior aspect, which is placed in the suprachoroidal space. The GMS Plus model weighs 9.2mg and has larger channels (68µ high). The shunt is designed to increase uveoscleral outflow from the anterior chamber into the suprachoroidal space through the channels. In some cases, aqueous may also flow around the shunt itself.

Proper positioning of the shunt results in anterior drainage openings located in the anterior chamber, visible by gonioscopy, and posterior holes in the suprachoroidal space, with the shunt entry into the anterior chamber just above the level of the scleral spur. The crescent-shaped anterior aspect of the shunt contains a positioning hole that can be used to adjust shunt positioning with an instrument such as a Sinsky hook. The posterior aspect

**Figure 1: SOLX Gold Suprachoroidal Shunt**

Note that the posterior aspect of the shunt is seen at the top of the photograph while the anterior aspect of the shunt is seen at the bottom of the photograph.

**Figure 2: Full-thickness Cut-down of the Sclera Is Carried Down to the Choroid While a Scleral Tunnel Incision Is Seen Anteriorly at 95% Scleral Thickness****Figure 3: The Gold Shunt Being Positioned Using a 27-gauge Short Hypodermic Needle on the Body of the Shunt**

of the shunt possesses two positioning tabs – one on each lateral side – for shunt manipulation. Flow is directed through the shunt via the natural pressure gradient from the anterior chamber to the suprachoroidal space.

### Surgical Technique

Topical anaesthesia with or without subconjunctival anaesthesia is used in most cases, with a corneal bridle suture if necessary. The gold shunt can be implanted in any quadrant, but the scleral tissue in the area of surgery should be healthy. Furthermore, the angle in the area of intended implantation should be open and free of any peripheral anterior synechia. Implantation of the gold shunt begins with a 4mm fornix-based

conjunctival peritomy. A vertical scleral incision (i.e. scleral cut-down) approximately 3.5mm in length is then created 2mm posterior from the limbus, or further posteriorly in highly myopic eyes. The dissection is carried out to near full-thickness depth, where the choroid is visible through a thin layer of sclera. A scleral pocket at 95% depth is then created, tunnelling anteriorly towards the scleral spur and stopped prior to entry into the anterior chamber. These steps should be performed with the eye pressurised to facilitate the scleral dissection. At this point, the vertical cut-down incision is deepened into the choroidal space (see *Figure 2*). A small amount of suprachoroidal anaesthesia and viscoelastic may be administered with a blunt cannula. To maintain the anterior chamber, a small amount of cohesive viscoelastic may be injected into the angle of anticipated surgical entrance, or an anterior chamber maintainer may be used; if viscoelastic is used, only a small amount should be injected, and it should be evacuated at the conclusion of the case. An entry is then made into the anterior chamber at the level of the scleral spur through the previously constructed scleral tunnel, ensuring that it is angled at the iris plane level.

The gold shunt should be handled with care, avoiding placement of forceps over the body of the implant so as not to crush the lumen. Using a 'push then pull' technique, the gold shunt is inserted through the scleral incision into the anterior chamber, leaving on the posterior tabs at the scleral cut-down. Positioning of the shunt into the suprachoroidal space is achieved by tucking the two posterior lateral tabs of the device into the suprachoroidal space and by using a sharp 27-gauge needle against the shunt to gently pull it into the suprachoroidal space (see *Figure 3*). Alternatively, an instrument such as a Sinsky hook can be utilised on the lateral tabs. The placement and movement of the shunt into the suprachoroidal space is assisted by slightly depressurising the eye to relax the choroid and facilitate opening of the supraciliary space. The posterior scleral lip of the wound should conceal all of the shunt openings on the posterior aspect. The anterior aspect of the shunt can also be manipulated through the anterior chamber to aid in the positioning of the implant. Intraoperative gonioscopy can be performed to confirm the proper and intended positioning of the gold shunt in the anterior chamber. No posterior drainage holes should be visible on gonioscopy, while most of the anterior drainage openings should be visible (i.e. 1.0mm into the anterior chamber). The shunt should also be allowed to sit deeply enough that the posterior holes are all adequately in the suprachoroidal space.

The overlying scleral wound is tightly sutured with four to five interrupted 10-0 nylon sutures to ensure watertight closure, as subconjunctival reservoir is not the intended mode of filtration in this surgical procedure. Finally, a 10-0 vicryl suture is used to close the conjunctiva (see *Figures 4 and 5*).

### Comments

Although the procedure is relatively straightforward, a number of important surgical pearls should be considered, some of which have been described earlier. Perhaps the most critical step of the procedure is the location and angulation of the entry into the anterior chamber. Too posterior an entry may result in bleeding and/or iris touch, while an excessively anterior entry may lead to corneal contact and endothelialisation of the head of the implant. Thus, particular attention must be made to external landmarks and depth of incision during the scleral dissection.

Proper watertight closure is important to avoid a bleb, and hence we suggest avoiding operating in areas of poor scleral health (i.e. thinning,

previous incisions, prior antimetabolite exposure). For this reason, and because we avoid a bleb, we do not hesitate to place the implant inferiorly (i.e. inferotemporal). This may be preferred even in virgin eyes to maintain healthy conjunctiva superiorly should a future trabeculectomy or seton be required.

Direct bleeding from the choroid, although a source of hesitancy for some, is exceedingly uncommon as long as the choroid is not directly incised. As it is fairly spongy and soft, this is rare with the techniques described. Decompressing the eye on entrance into the space is also helpful to facilitate passage of the implant into the suprachoroidal area.

Once the shunt is properly positioned and ocular tension is normalised, there is little risk of implant migration as the sclera and choroid tend to hold it in place like a cushion. In our experience, we have not seen post-operative shunt migration. Post-operative re-positioning, when performed, is typically due to improper positioning at the time of surgery.

### Preliminary Data

The gold shunt is currently under investigation in a multicentre, randomised phase III FDA study from which data are not currently available for publication. However, non-randomised clinical data collected from several investigators are presented below.

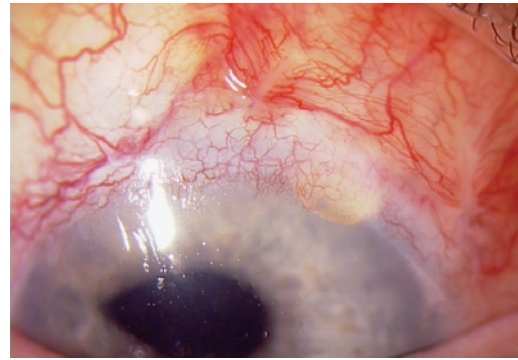
In patients with at least one previous failed incisional procedure for glaucoma, there was a 33% reduction in IOP at one year with the GMS model, with a mean pre-operative IOP of  $27.4 \pm 4.7$  mmHg compared with  $18.1 \pm 4.7$  mmHg post-operatively in a group of 39 patients. The GMS Plus model showed a similar reduction in IOP, from  $25.5 \pm 6.0$  to  $18.0 \pm 2.5$  mmHg at one year in a group of 40 patients. The GMS group decreased their number of topical medications from  $1.97 \pm 0.74$  to  $1.50 \pm 0.94$ , while the GMS Plus group decreased from  $2.25 \pm 0.84$  topical medications pre-operatively to  $0.85 \pm 0.90$  at one year. With success defined as IOP  $>5$  mmHg and  $<21$  mmHg, 10 of the final 36 patients in the GMS group at one year were classified as failures. Using the same criteria, in the GMS Plus group three of the final 13 patients had inadequate IOP control.

Complications seen to date with the gold shunt most commonly include anterior chamber inflammation, hyphema, hypotony and blurred vision, all of which are minor and transient in nature and normally resolve completely by one or two weeks. Data thus far indicate that serious adverse events are rare.

### Conclusion

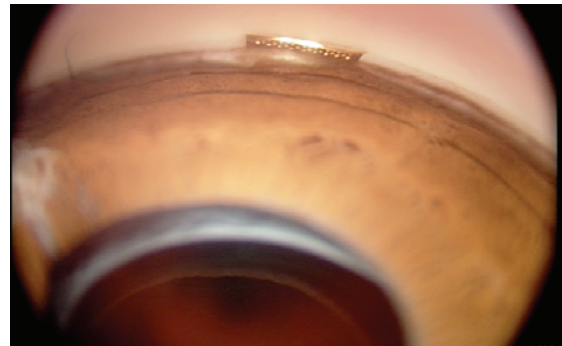
Subconjunctival filtration surgery, currently the mainstay of surgical therapy in the treatment of glaucoma, relies on the long-term maintenance of a bleb for successful control of IOP. However, blebs present both short- and long-term risk of complications to patients and are susceptible to fibrosis and failure even with the use of antimetabolic or antifibrotic agents. Surgery to encourage

**Figure 4: Post-operative Slit-lamp Photograph of the Gold Shunt**



Note the absence of a bleb over the shunt but the presence of a previous failed trabeculectomy to the left of the shunt.

**Figure 5: Post-operative Gonioscopic Photograph of the Gold Shunt in the Anterior Chamber Emerging Through the Scleral Spur**



suprachoroidal outflow, such as the creation of cyclodialysis clefts or suprachoroidal seton placement, likewise has limitations in terms of unpredictability of long-term IOP control and concerns regarding the placement of a large, bulky foreign body in the suprachoroidal space, respectively.

For those patients who have demonstrated a failure of subconjunctival filtration or exuberant fibrotic responses, or who are poor candidates for subconjunctival surgery, suprachoroidal shunts such as the SOLX gold shunt may represent a significant development in glaucoma therapy. Furthermore, as this treatment is unlikely to preclude further traditional glaucoma surgery and appears to have a low risk profile, it is becoming an earlier surgical option or replacing trabeculectomy in various parts of the world. While the SOLX gold shunt is still in phase III FDA clinical trials, the device concept, design and results to date show that it may represent a significant development in glaucoma surgical options. Further study and development in this area and of this device are needed and may advance our knowledge of suprachoroidal shunting and enhance the treatment options for glaucoma patients. Although studies remain to be completed on this device, it represents a potentially attractive and effective future option for glaucoma surgeons. ■

1. Bill A, Phillips CI, *Exp Eye Res*, 1971;12:275–81.
2. Toris CB, Yablonski ME, Wang YL, et al., *Am J Ophthalmol*, 1999;127:407–12.
3. Emi K, Pederson JE, Toris CB, *Inv Oph Vis Sci*, 1989;30(2):233–8.
4. Suguro K, Toris CB, Pederson JE, *Invest Ophthalmol Vis Sci*, 1985;26:810–13.
5. Jordan JF, Dietlein TS, Dinslage S, et al., *Graefes Arch Clin Exp Ophthalmol*, 2007;245:1071–6.
6. Shields MB, Simmons RJ, *Ophthalmic Surg*, 1976;7(2):62–73.
7. Galin MA, Baras I, *Ann Ophthalmol*, 1975;7(2):271–5.
8. Gills Jr. JP, Paterson CA, *Exptl Eye Res*, 1967;6:75–8.
9. Klemm M, Balazs A, Draeger J, Wieszorrek R, *Graefes Arch Clin Exp Ophthalmol*, 1995;233(9):592–7.
10. Nesterov AP, Batmanov YE, Cherkasova IN, Egorov EA, *Acta Ophthalmologica*, 1979;57(3):409–17.
11. Pinnas G, Boniuk M, *Am J Ophthalmol*, 1969;68(5):879–83.
12. Krejci L, *Ophthalmologica*, 1972;164:113–21.
13. Ozdamar A, Aras C, Karacorlu M, *J Glaucoma*, 2003;12:354–9.
14. Jordan JF, Engels BF, Dinslage S, et al., *J Glaucoma*, 2006;15:200–205.
15. Yablonski ME, *J Glaucoma*, 2005;14:91–7.
16. Eisler R, *Biol Tr Elem Res*, 2004;100:1–17.
17. Sen SC, Ghosh A, *Br J Ophthalmol*, 1983;67:398–9.